

Denture making


Procedure to make a denture

✿ Impression

✿ Wax rim : vertical height, facial harmony

✿ Esthetic try in

✿ Delivery

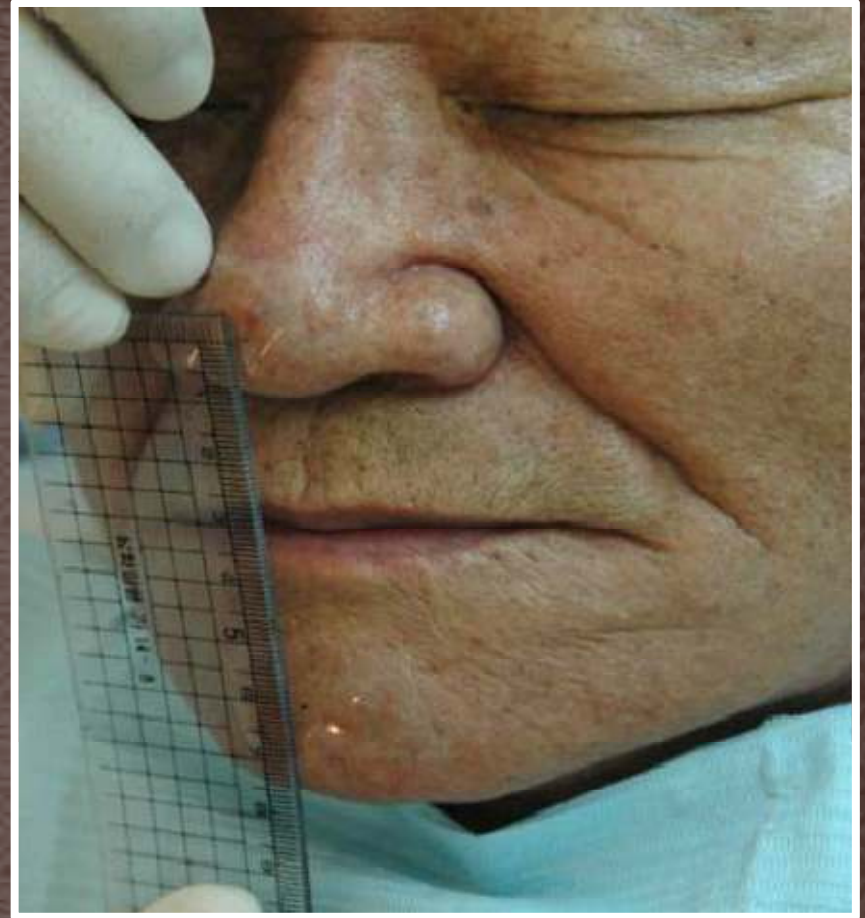
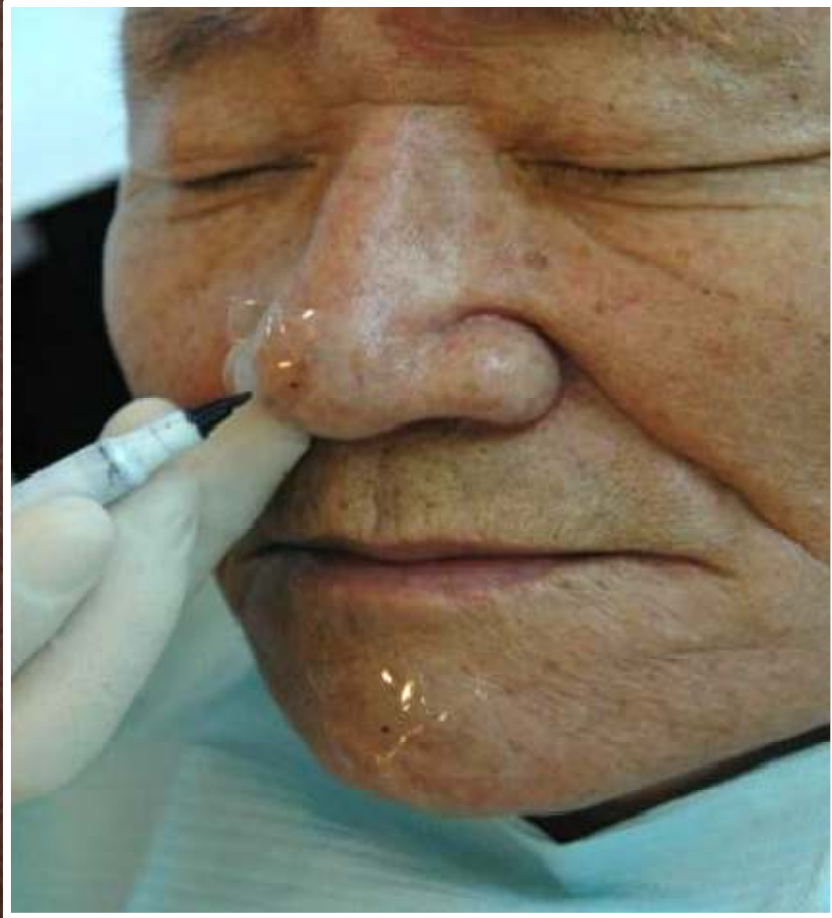

Vertical height & facial harmony with an occlusal plane plate



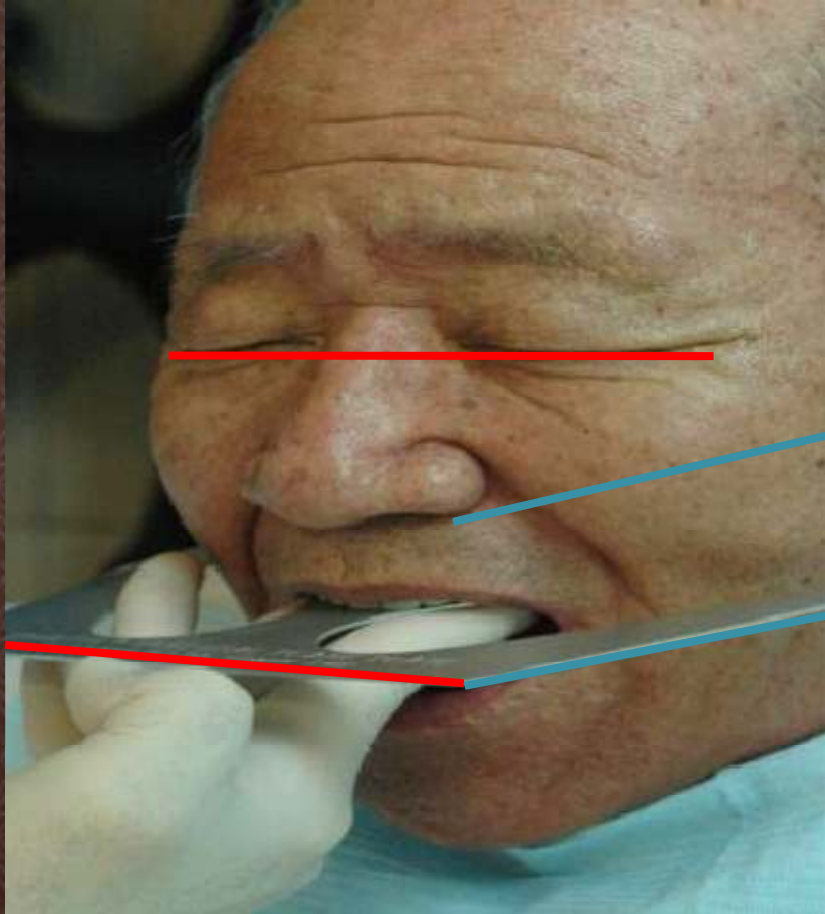
Occlusal plane plate, tape , ruler, oil-based pen

Vertical height measuring using a temp. denture

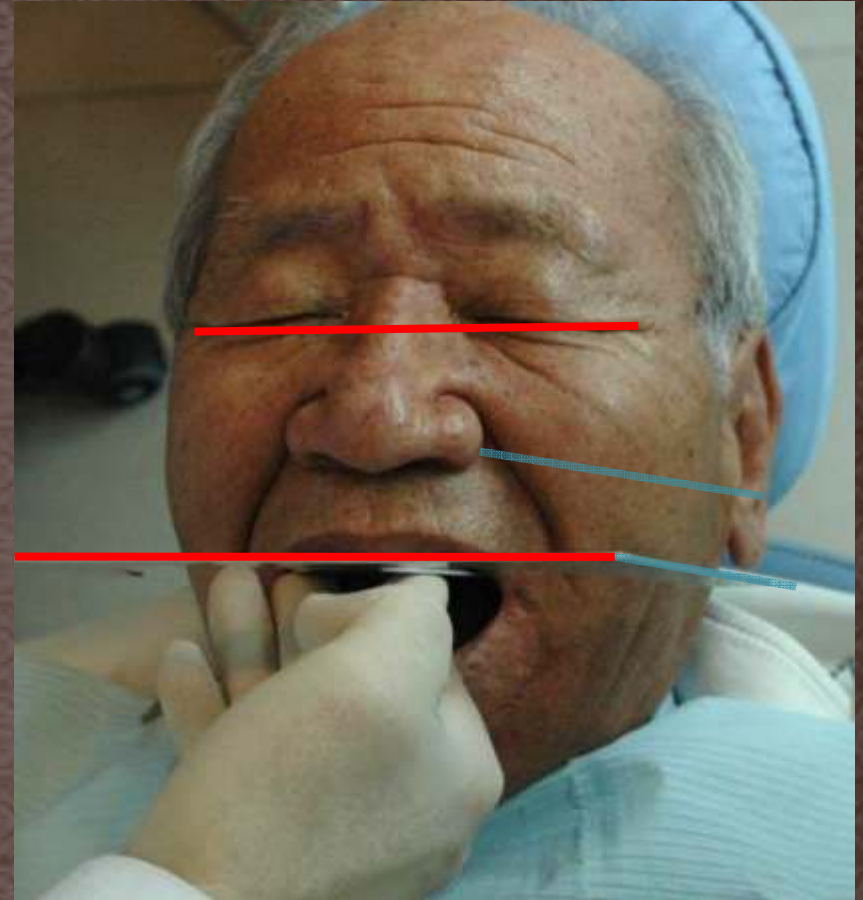


A new wax rim should be same height as an existing denture when tissue being relaxed 😊

Vertical height measuring using a temp. denture



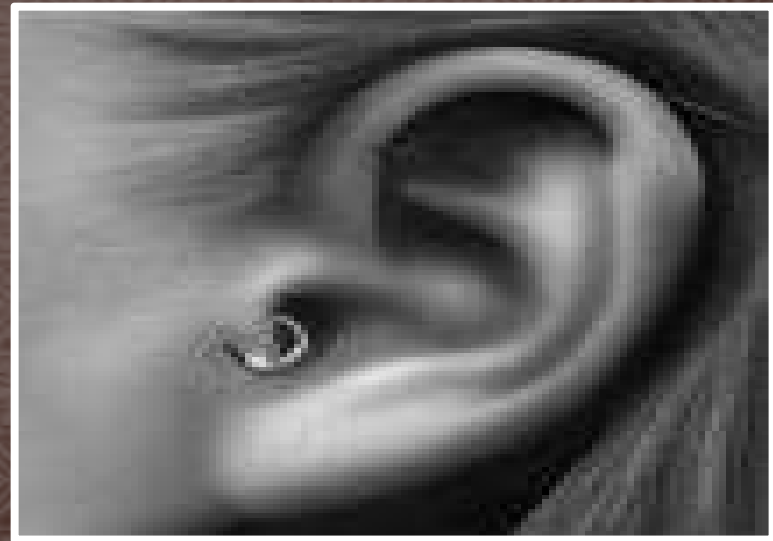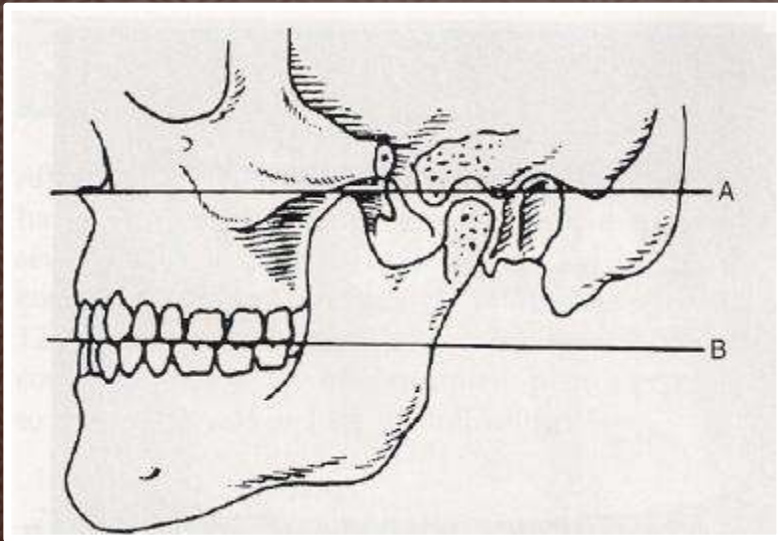
Ala-tragus line
occ.plane of upper occ.rim

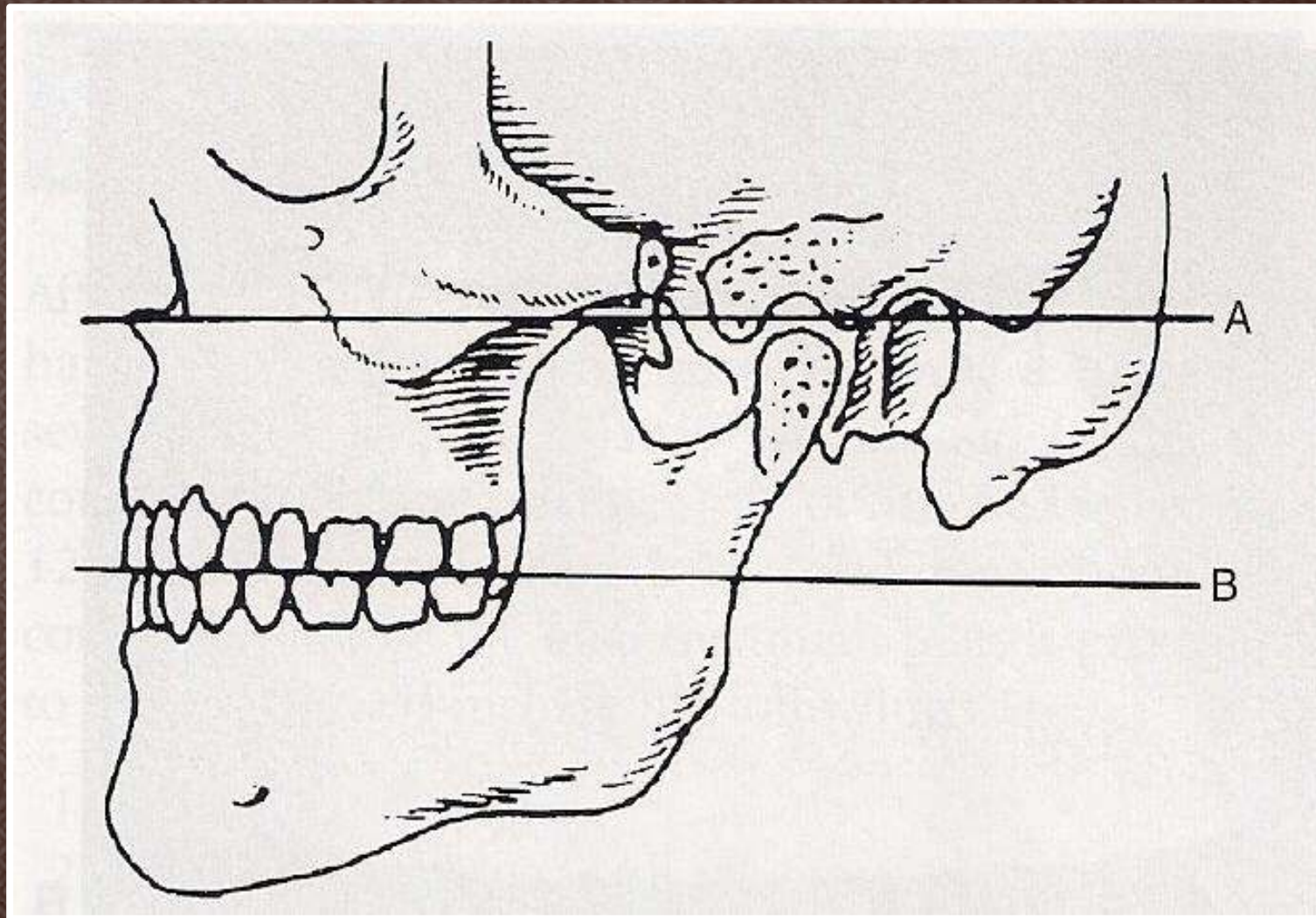


Interpupillary line
upper incisal plane

ala-tragus line


- ✿ a line running from the inferior border of the ala of the nose to some defined point on the tragus of the ear, usually considered to be the tip of the tragus





Ala-tragus line (A) is parallel to the occ.plane of max. teeth (B)

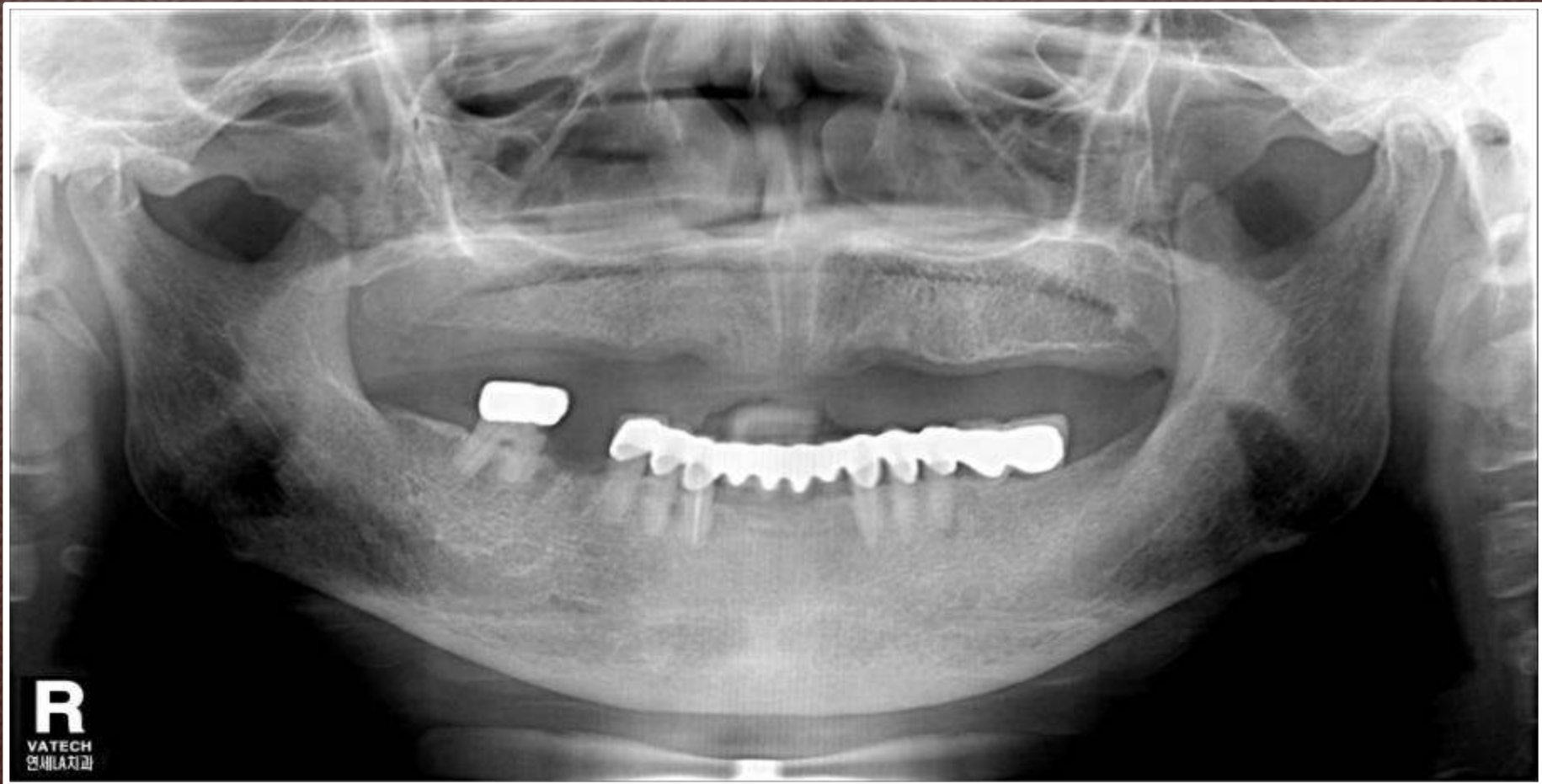
Facial harmony is important

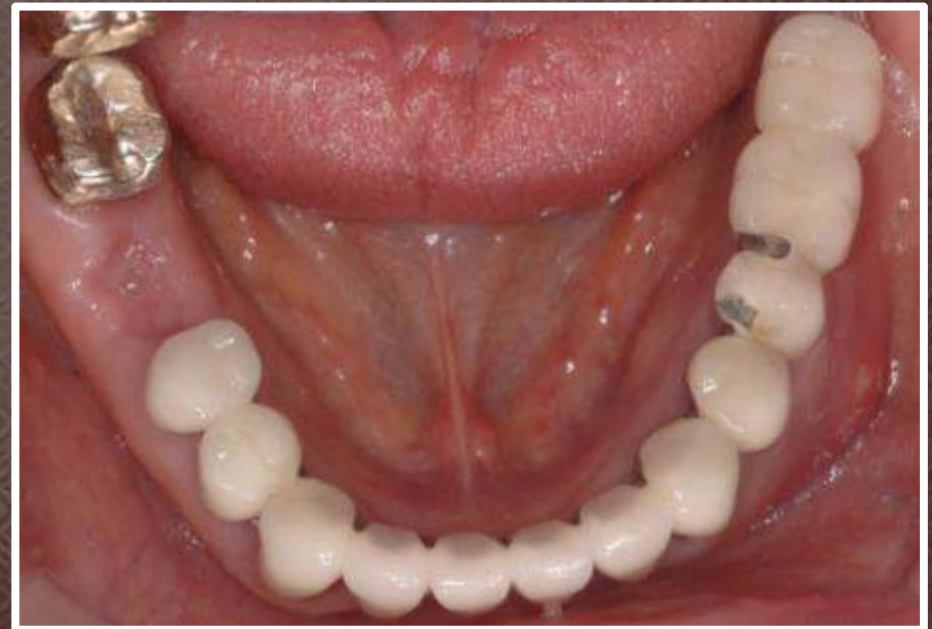
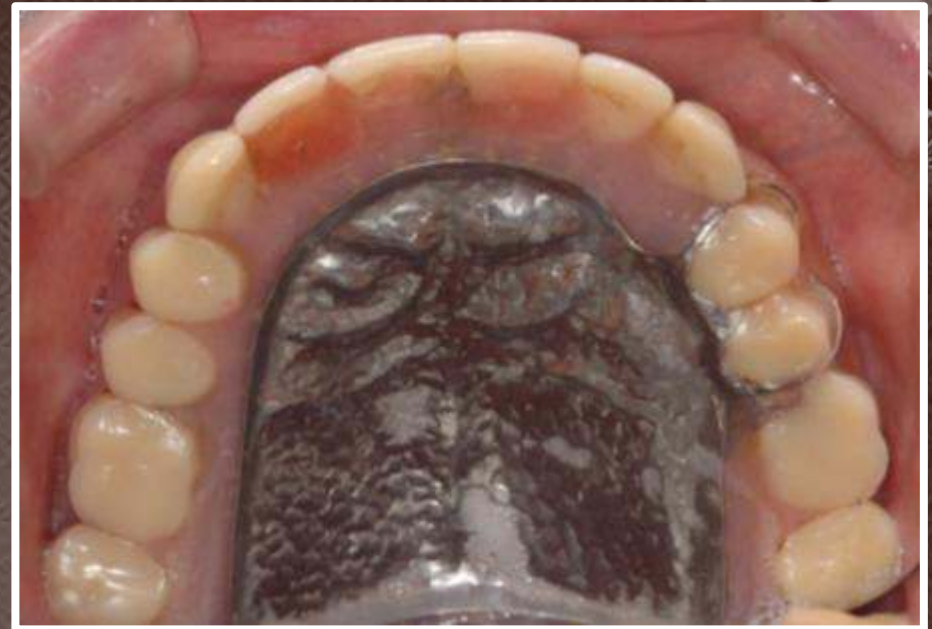
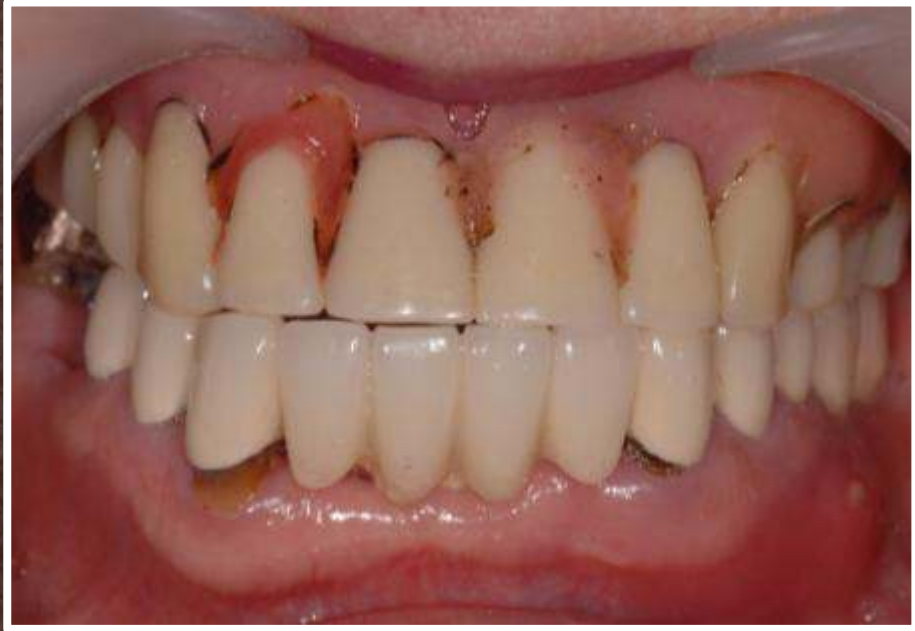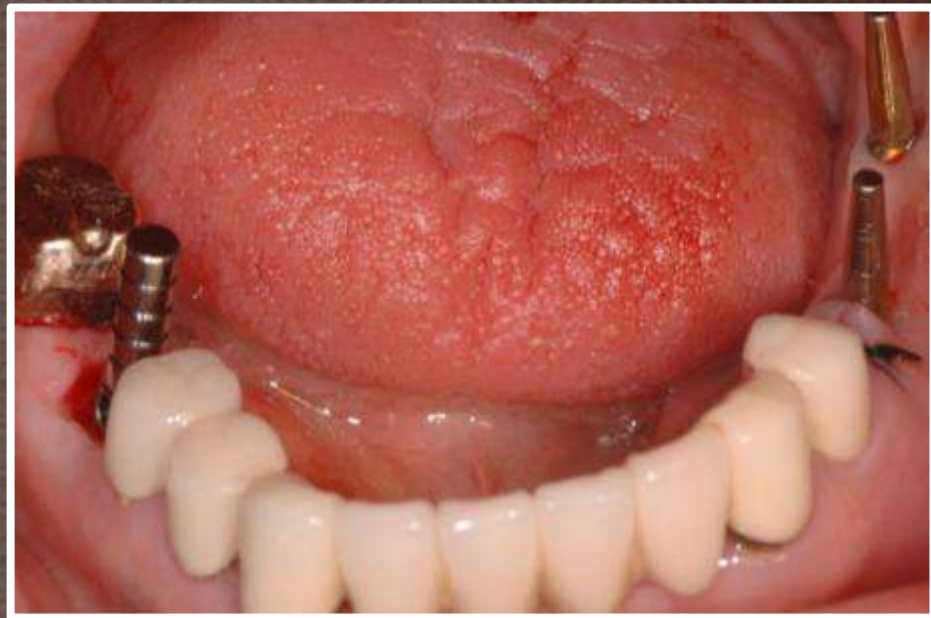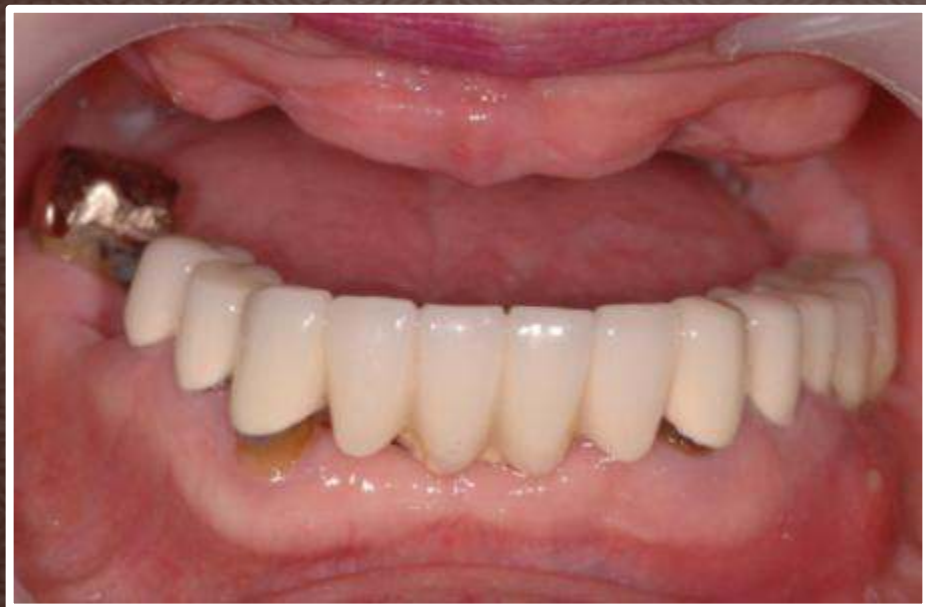Tooth color, shade, facial harmony 😊

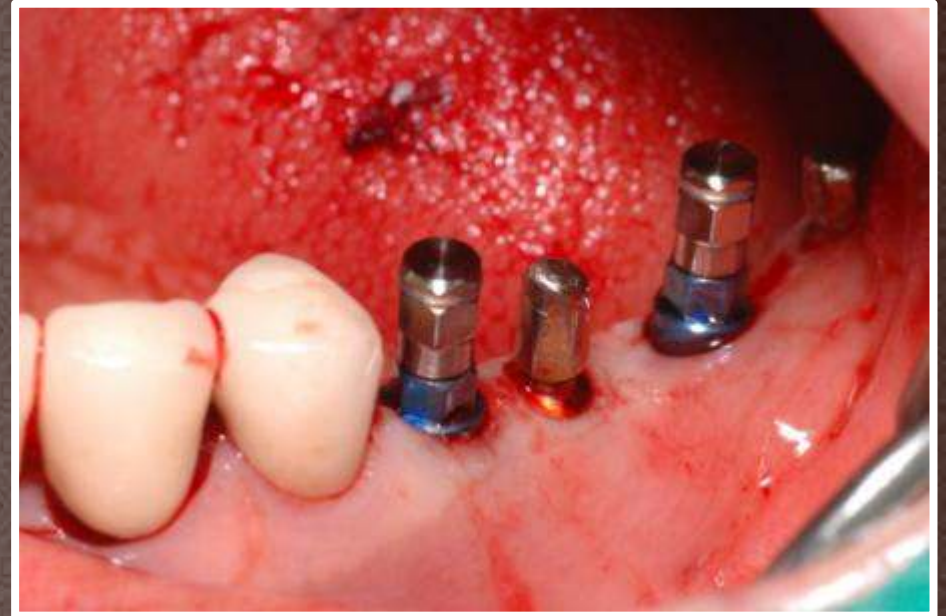
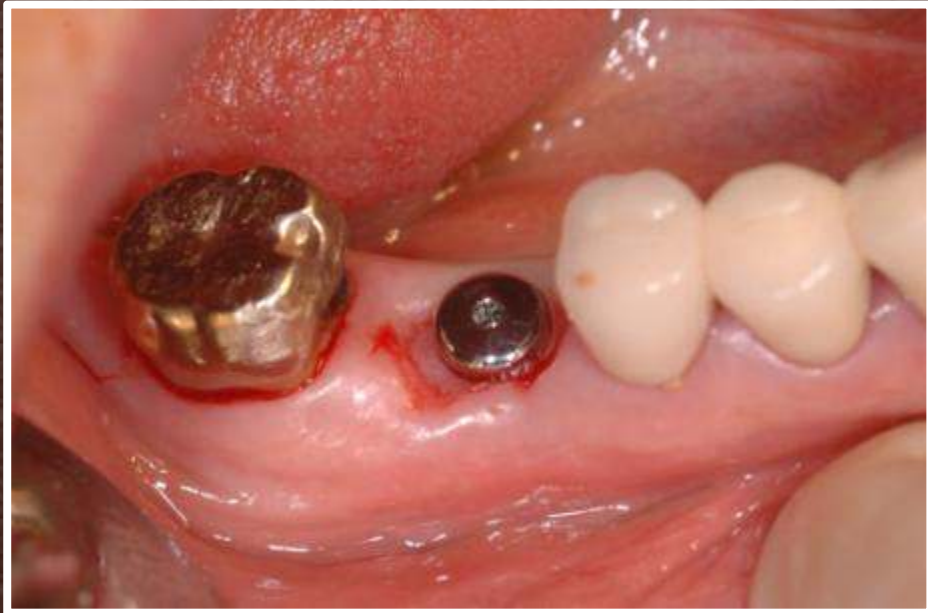Case

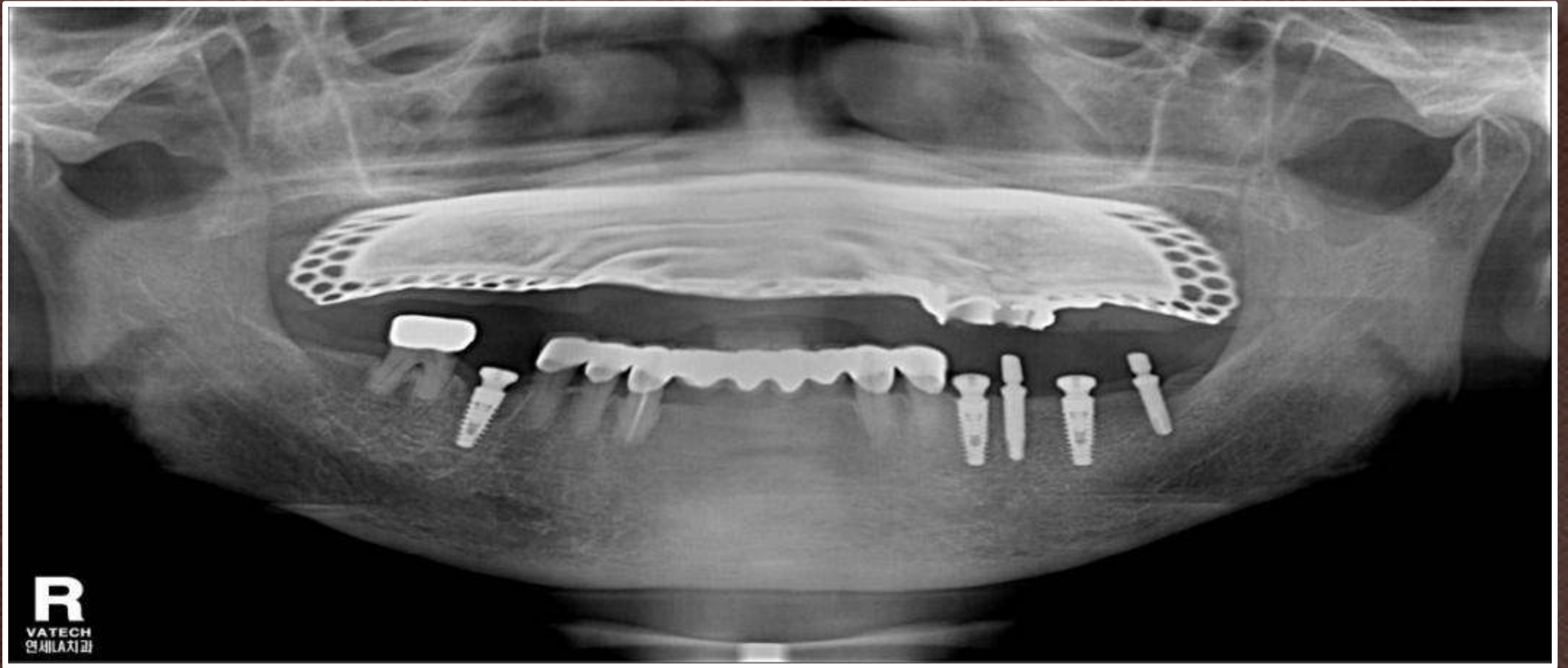
✿ 70 yr old woman





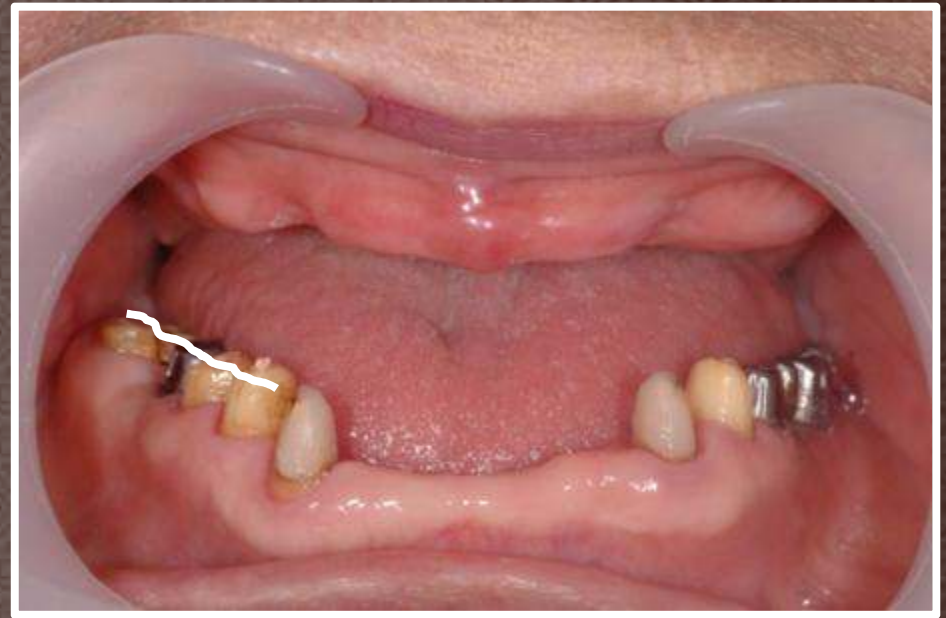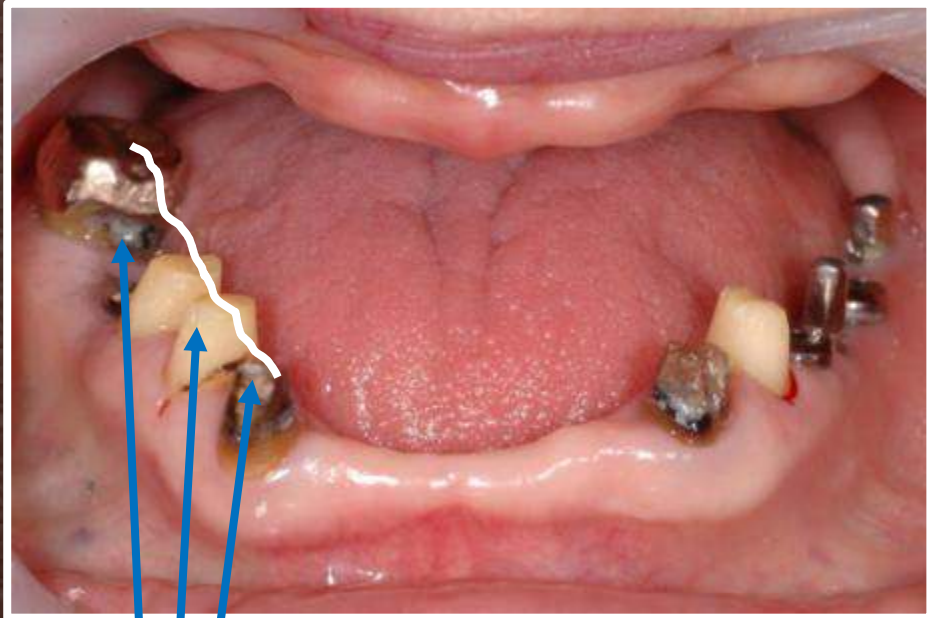




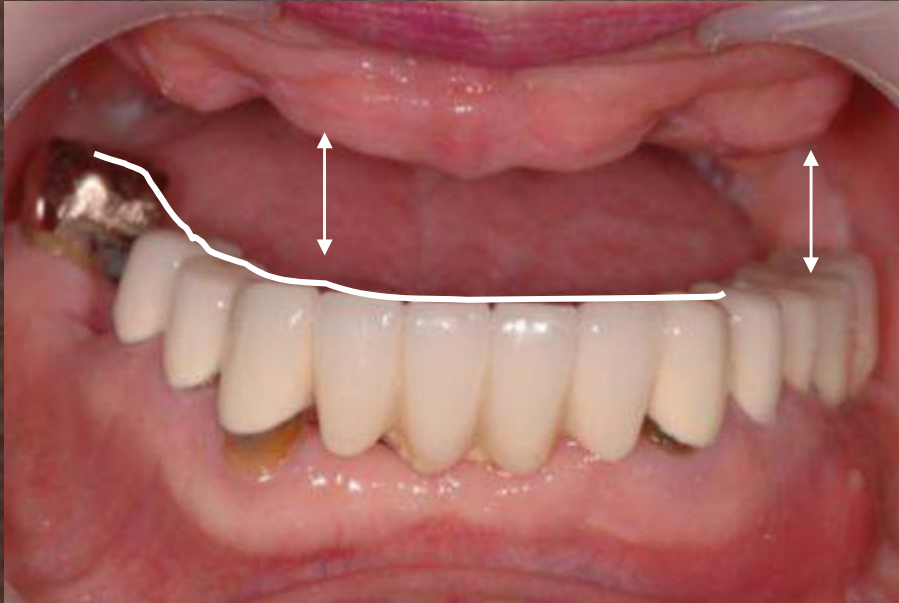


R

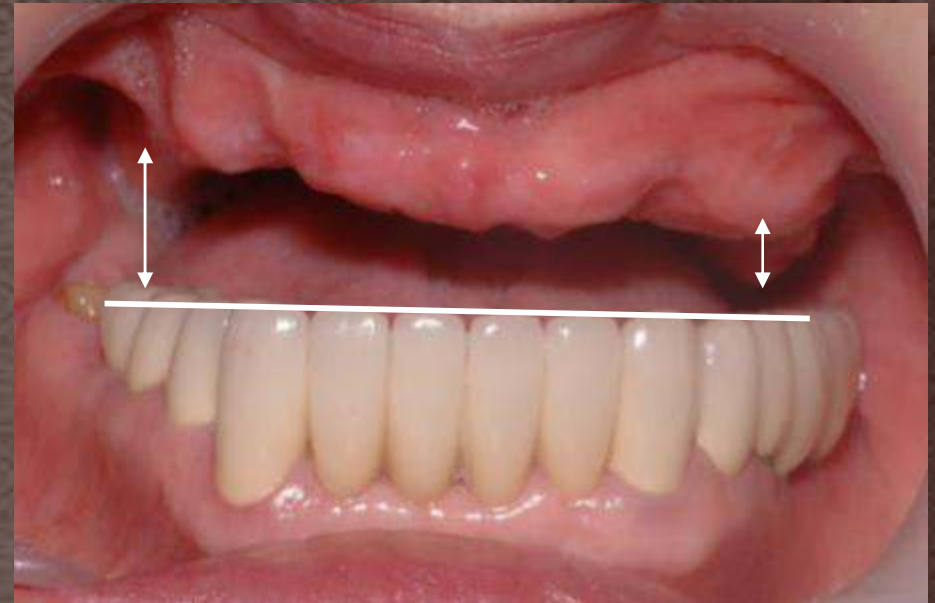
VATECH
연세치과



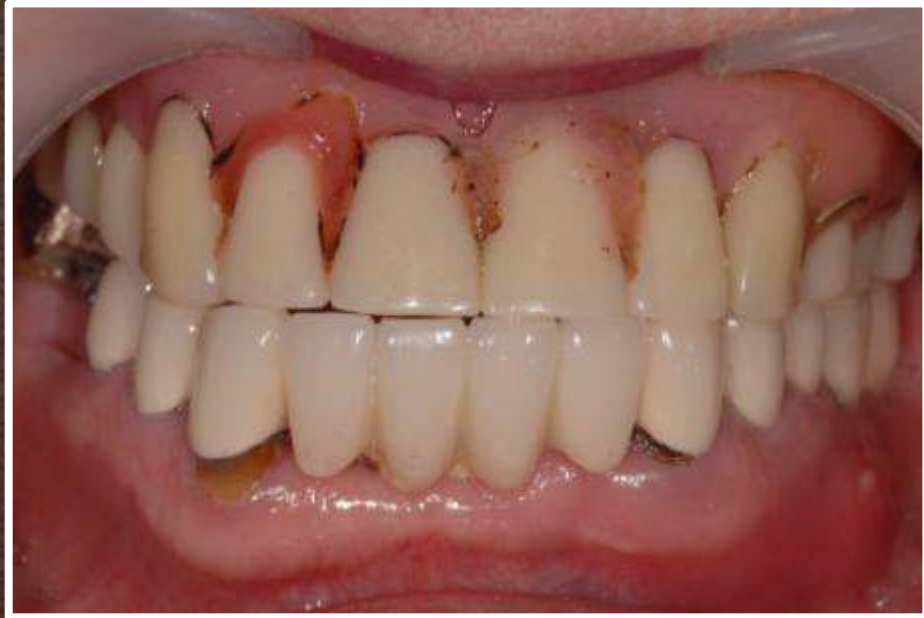CLP & Root canal tx



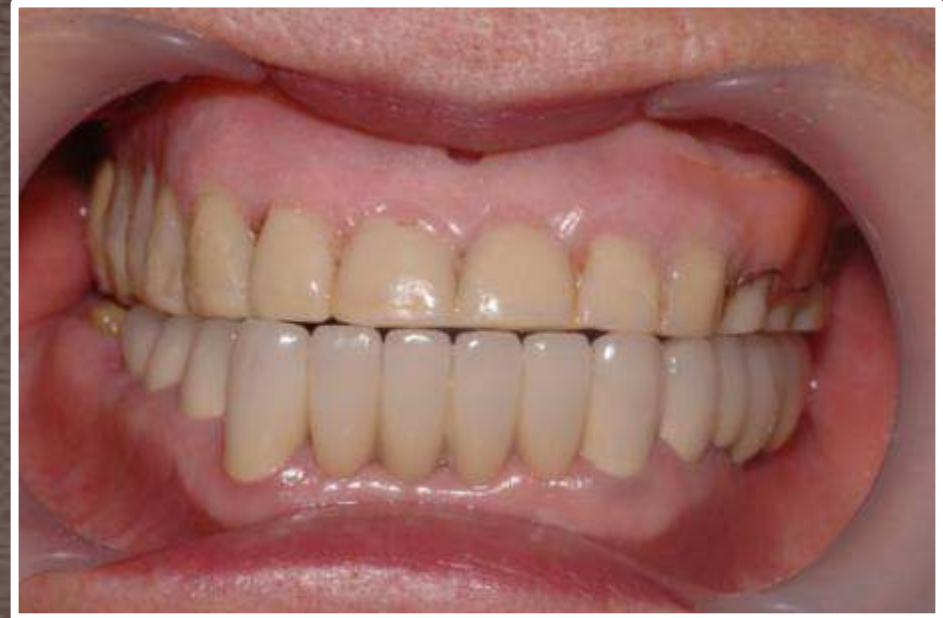What if ignored occlusal plane?



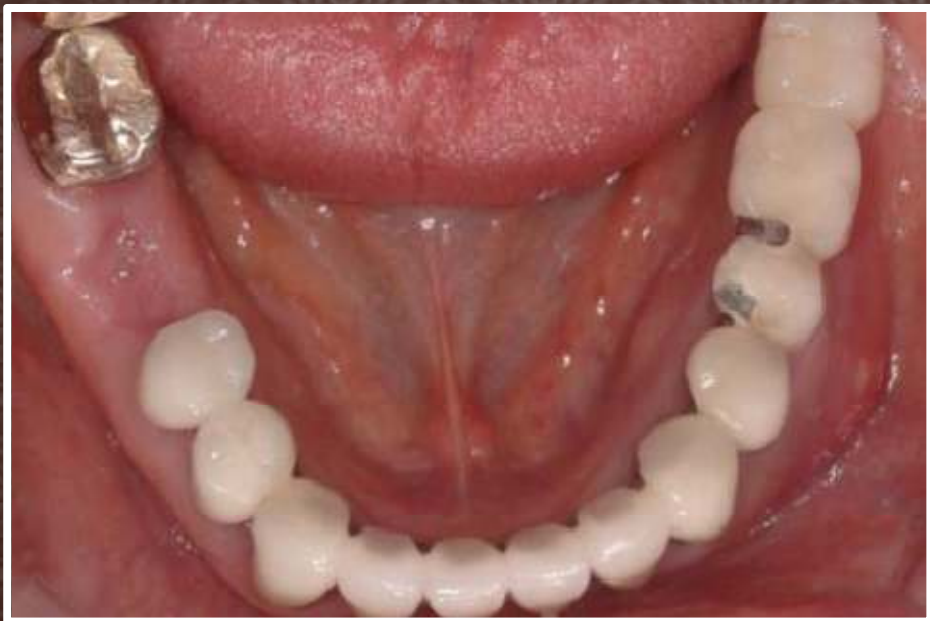**Upper denture might be unstable.
(hard to get balanced occlusion)**



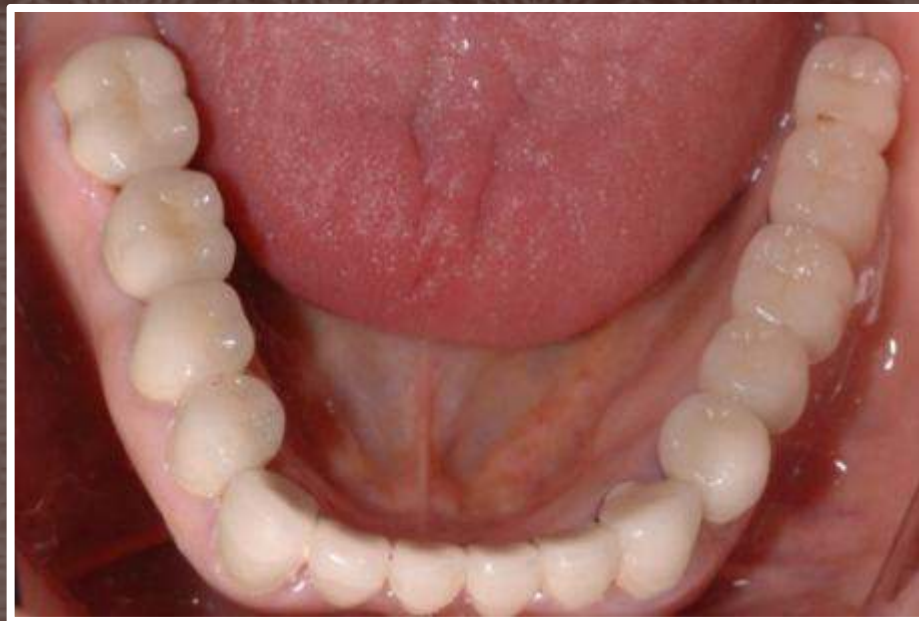Initial



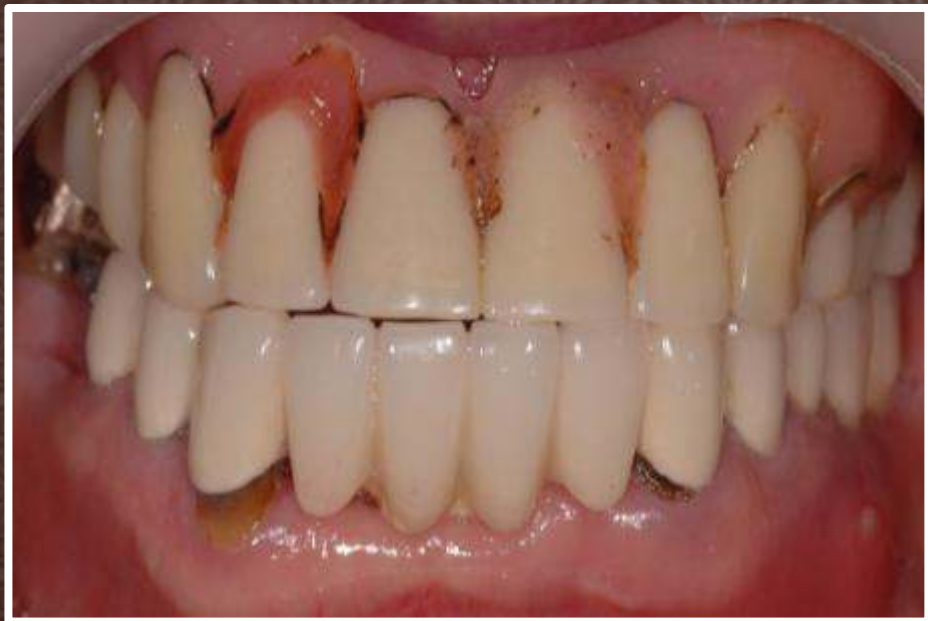**Corrected upper
temporary denture & lower crowns**



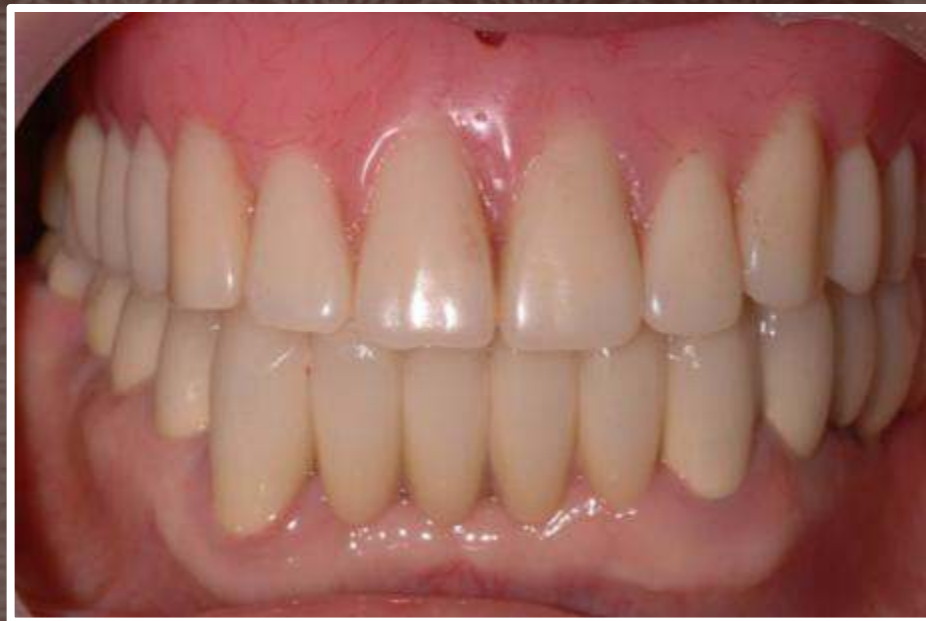Initial



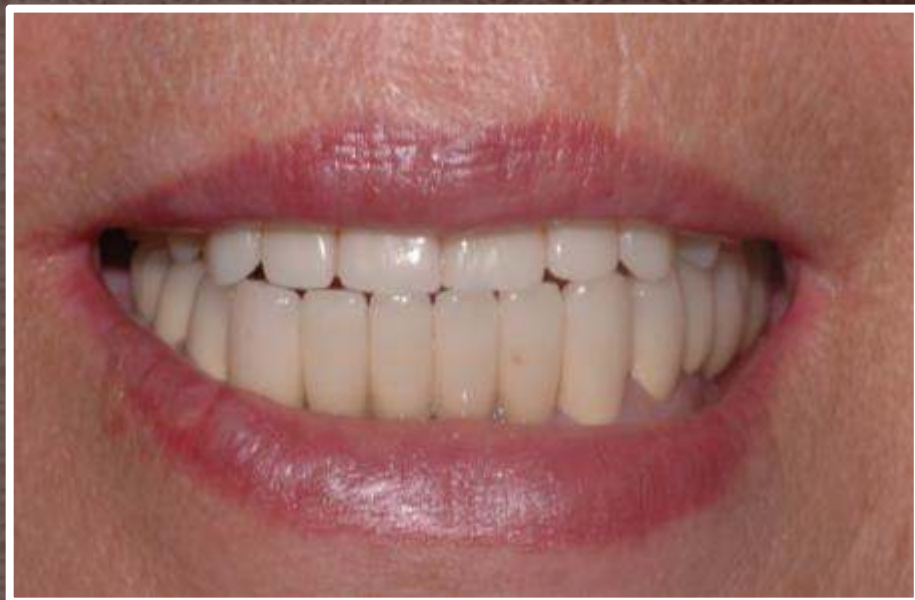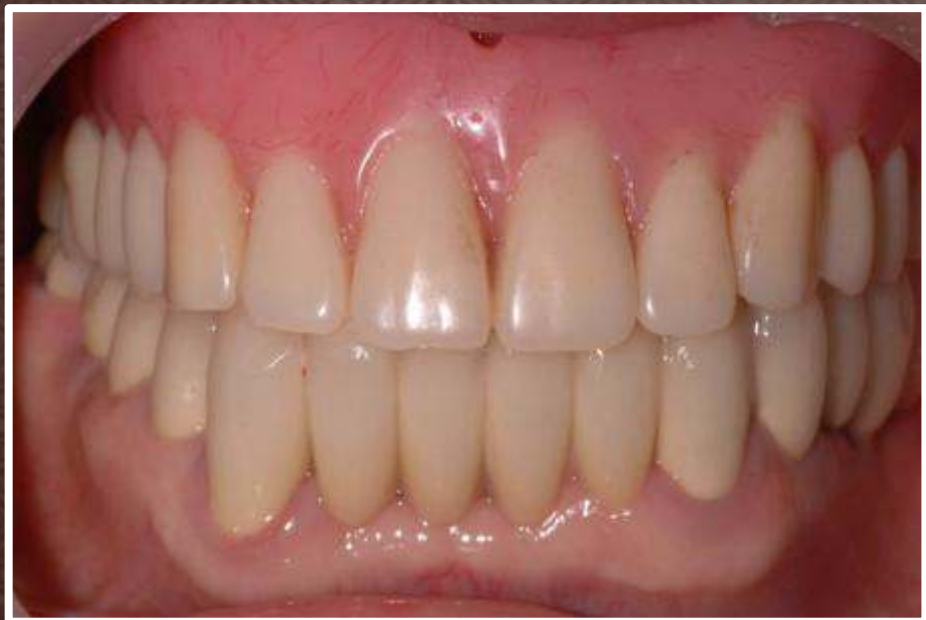Final

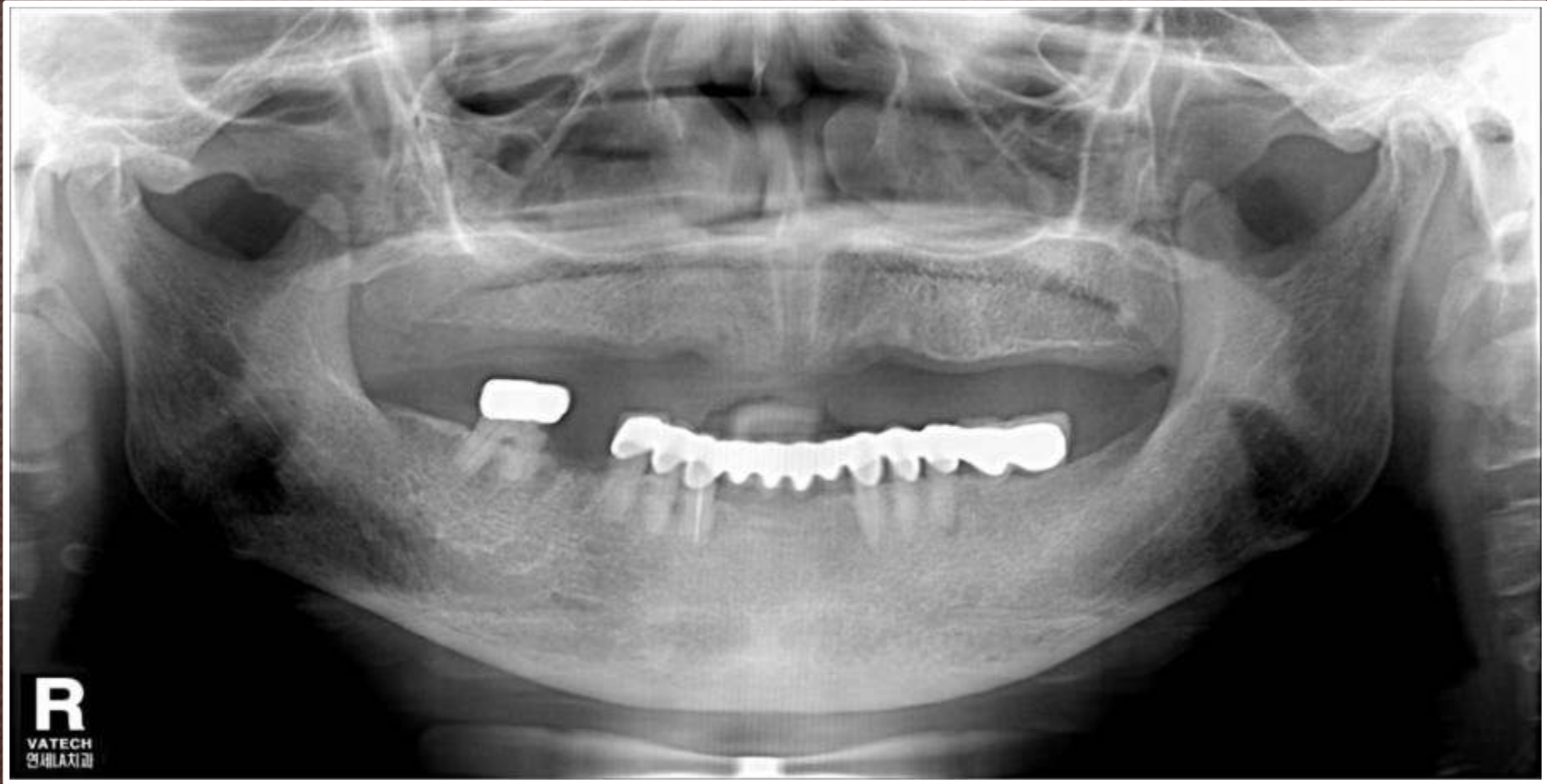


Initial

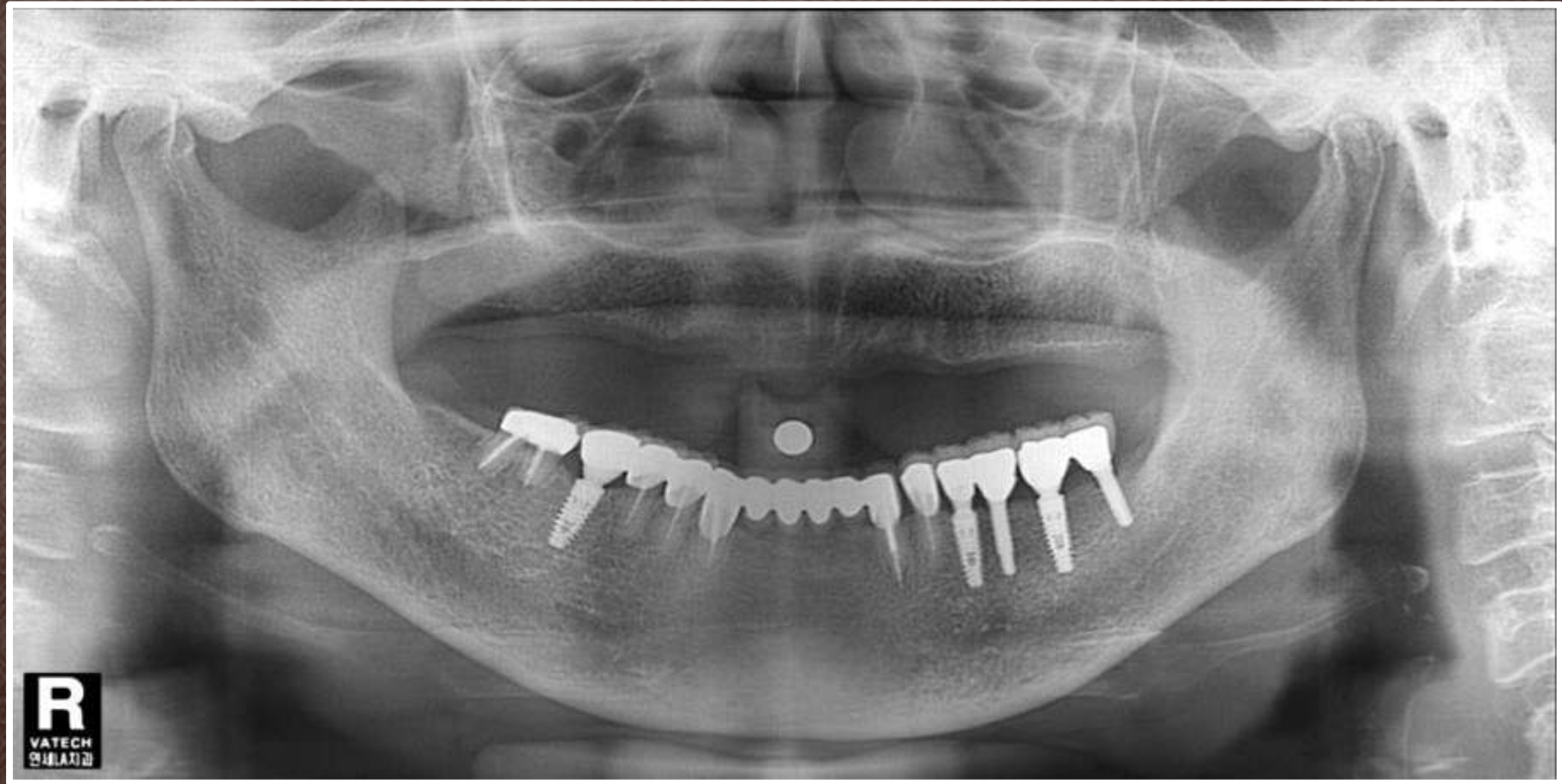


Final





Initial



Final


Occlusion

✿ Depends on upper condition

* Upper edentulous state

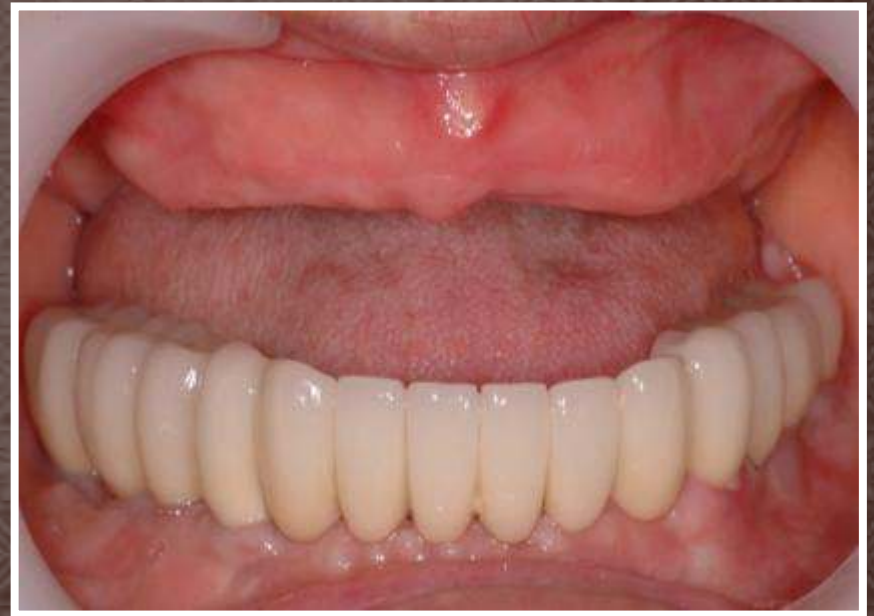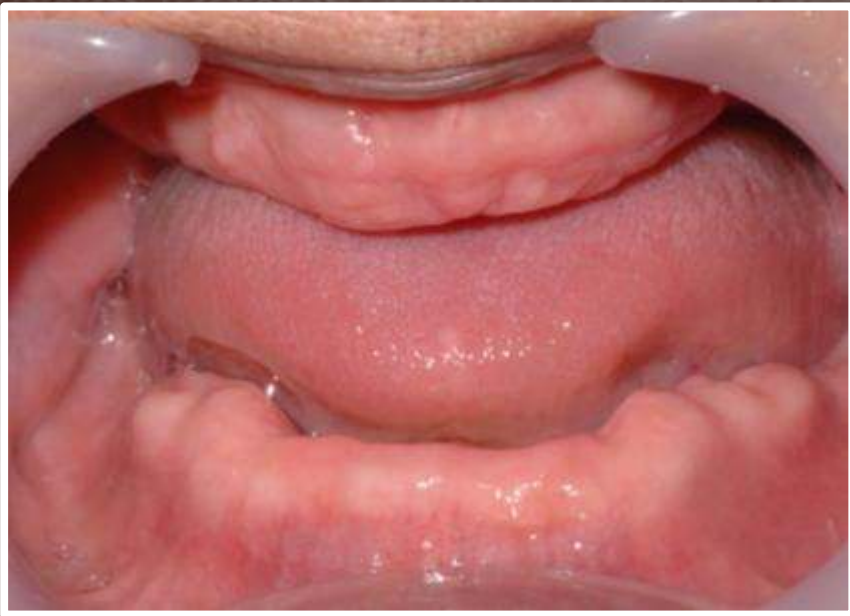* Unilaterally remaining teeth

* Fully dentulous state



Occlusion

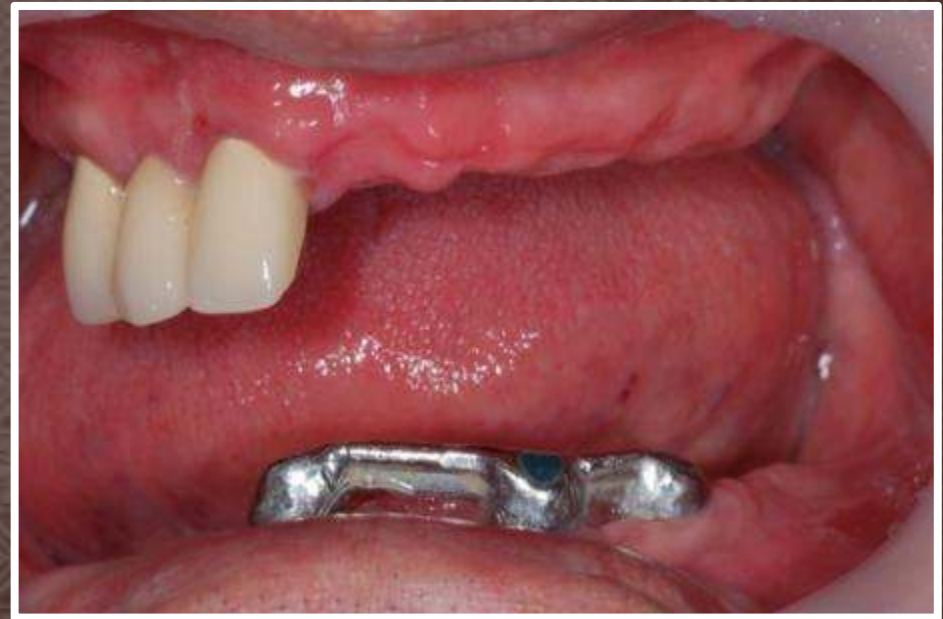- ✿ Upper edentulous state
" For denture stability "
: Bilateral balanced occlusion



Occlusion

- ✿ **Unilaterally remaining upper teeth : extraction for the denture stability**

if unilaterally remaining teeth exist,
tendency to chew the teeth side,
unstable upper denture,
opposing bone resorption

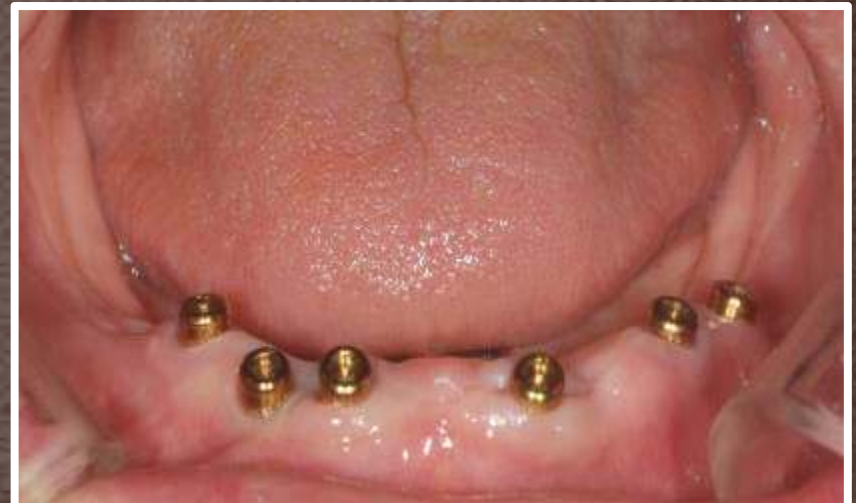
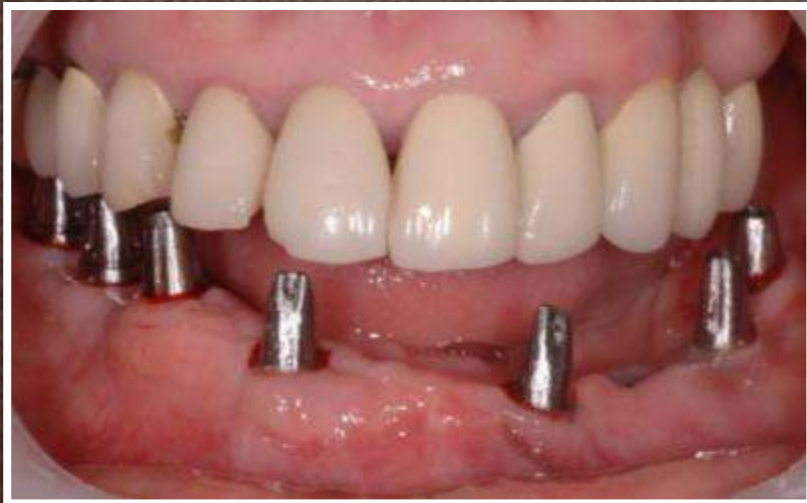
Occlusion

✿ Upper fully dentulous state

✿ Lower

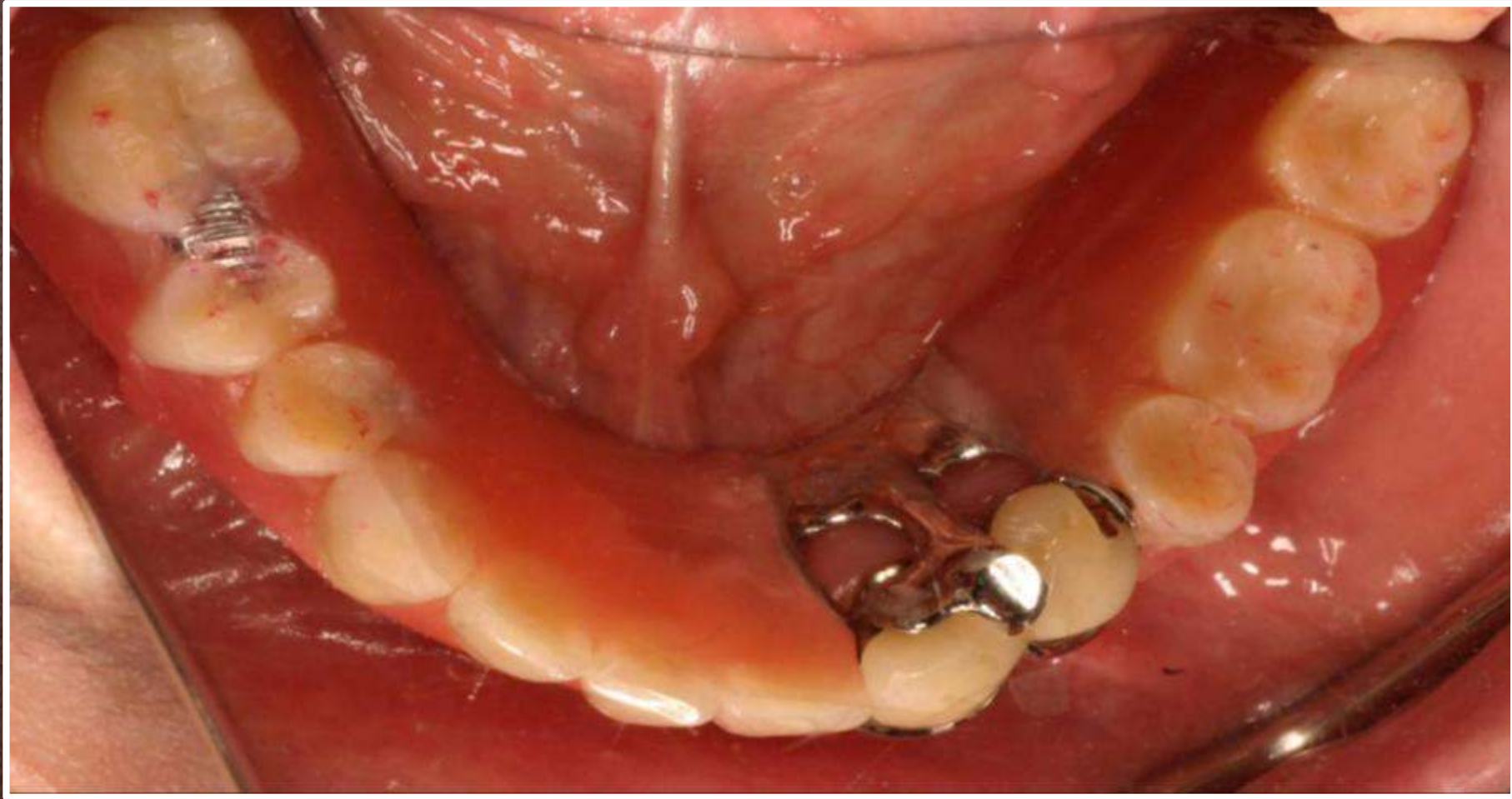
implant support overdenture 5-6 / or fixed type 8-10



**What is the benefits of
the implant attachments
to the R.P.D.**

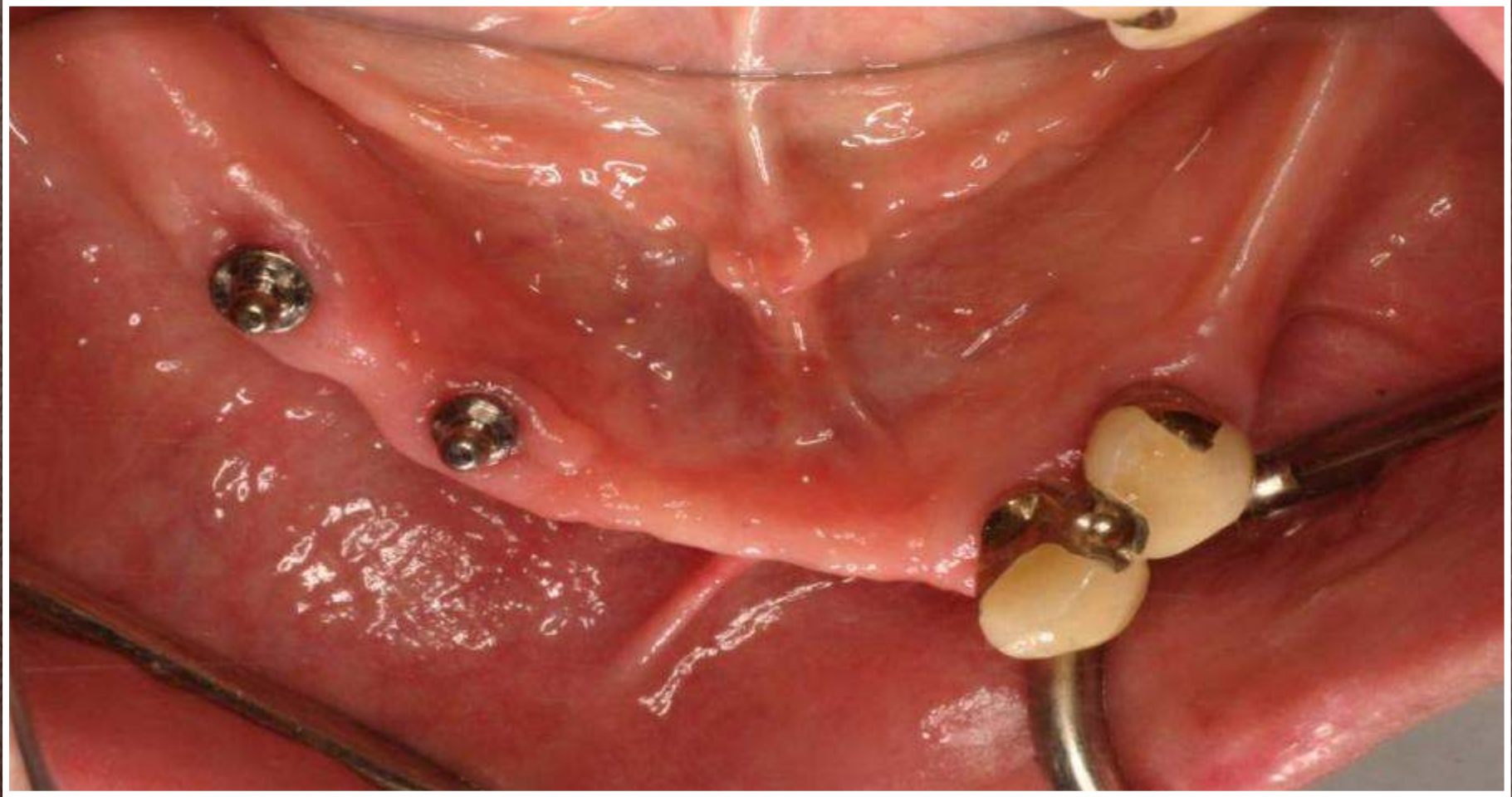


Case



By Lee JH

Case



By Lee JH

Case



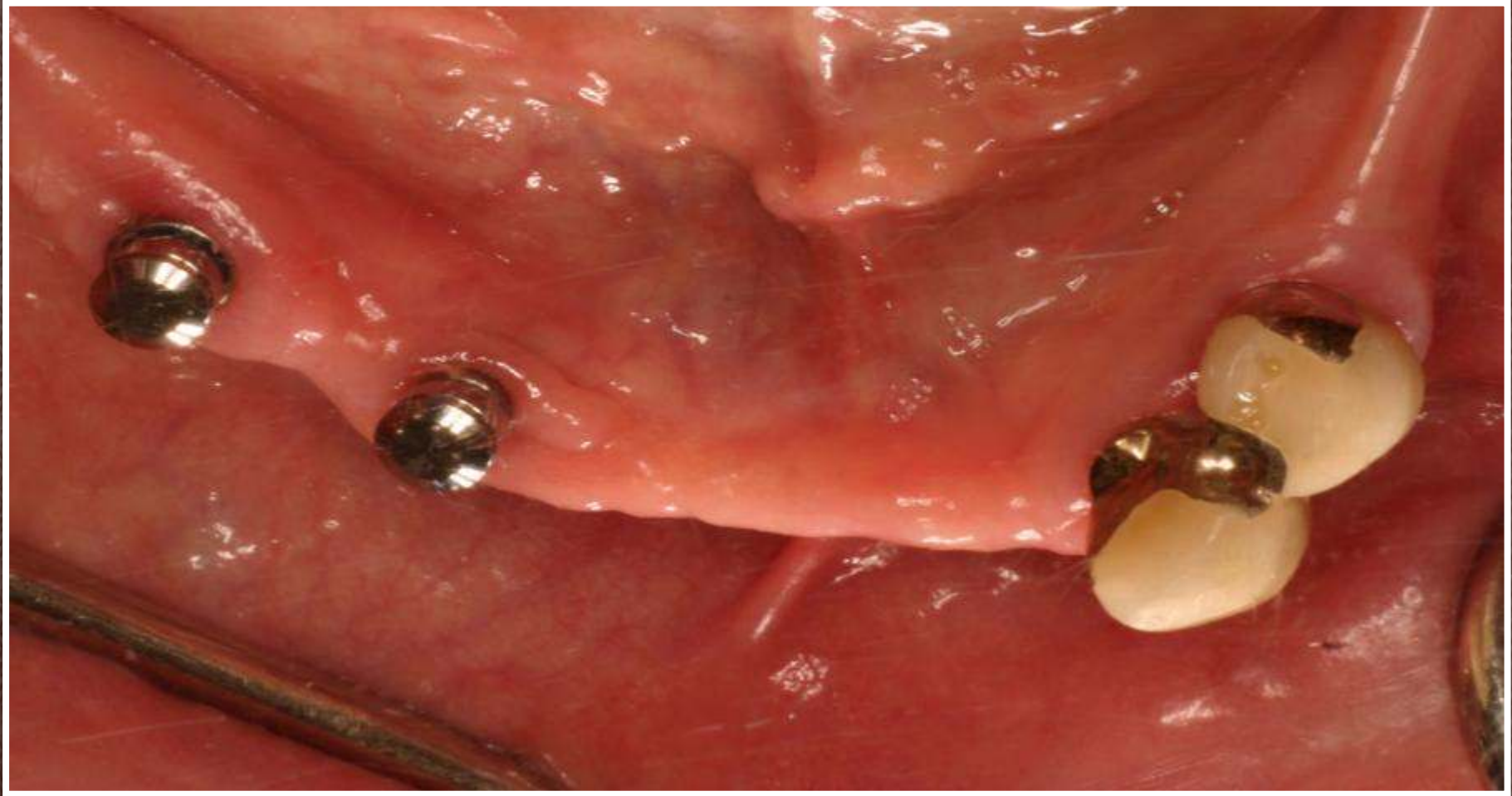
By Lee JH

Case



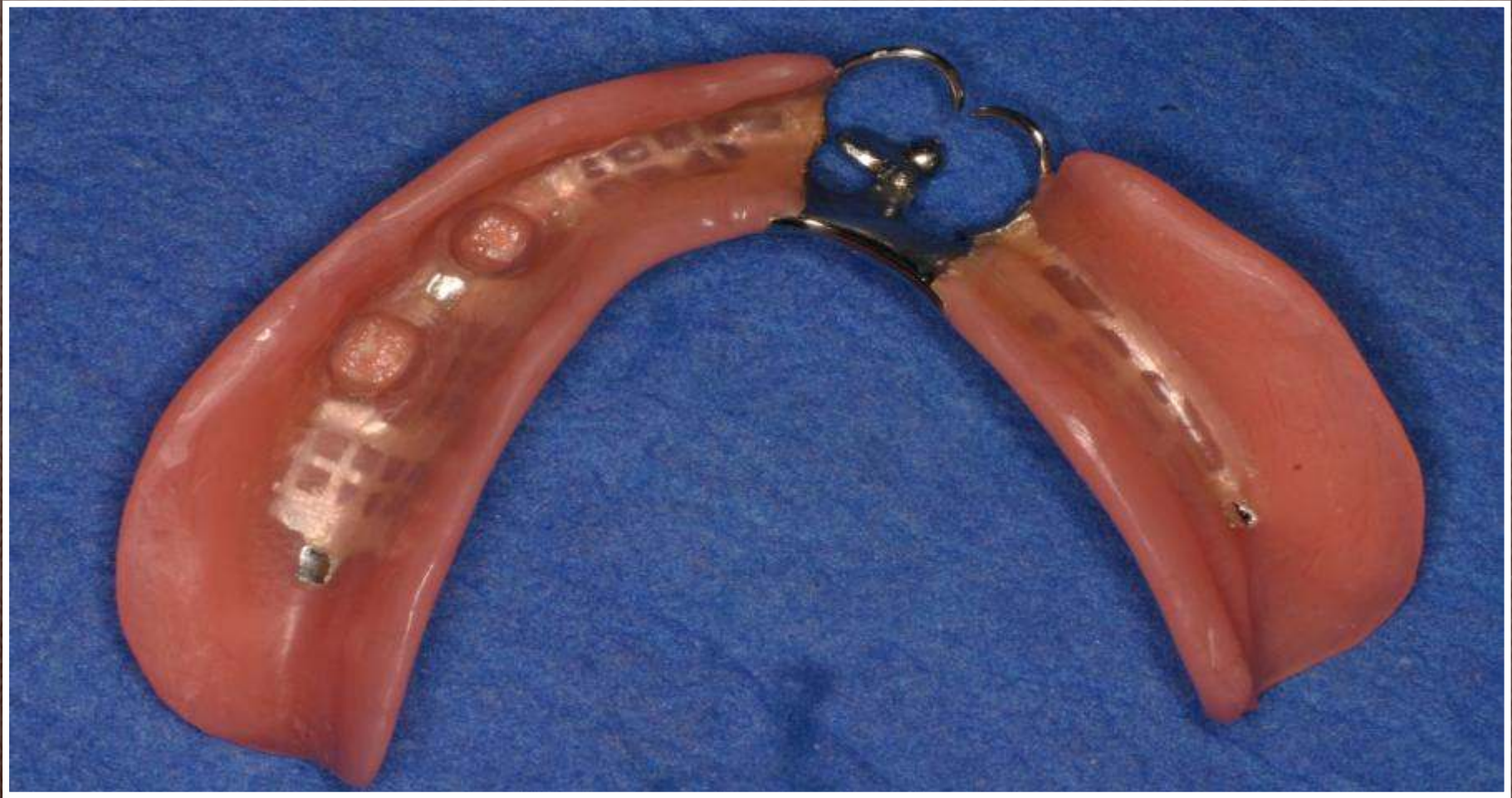By Lee JH

Case



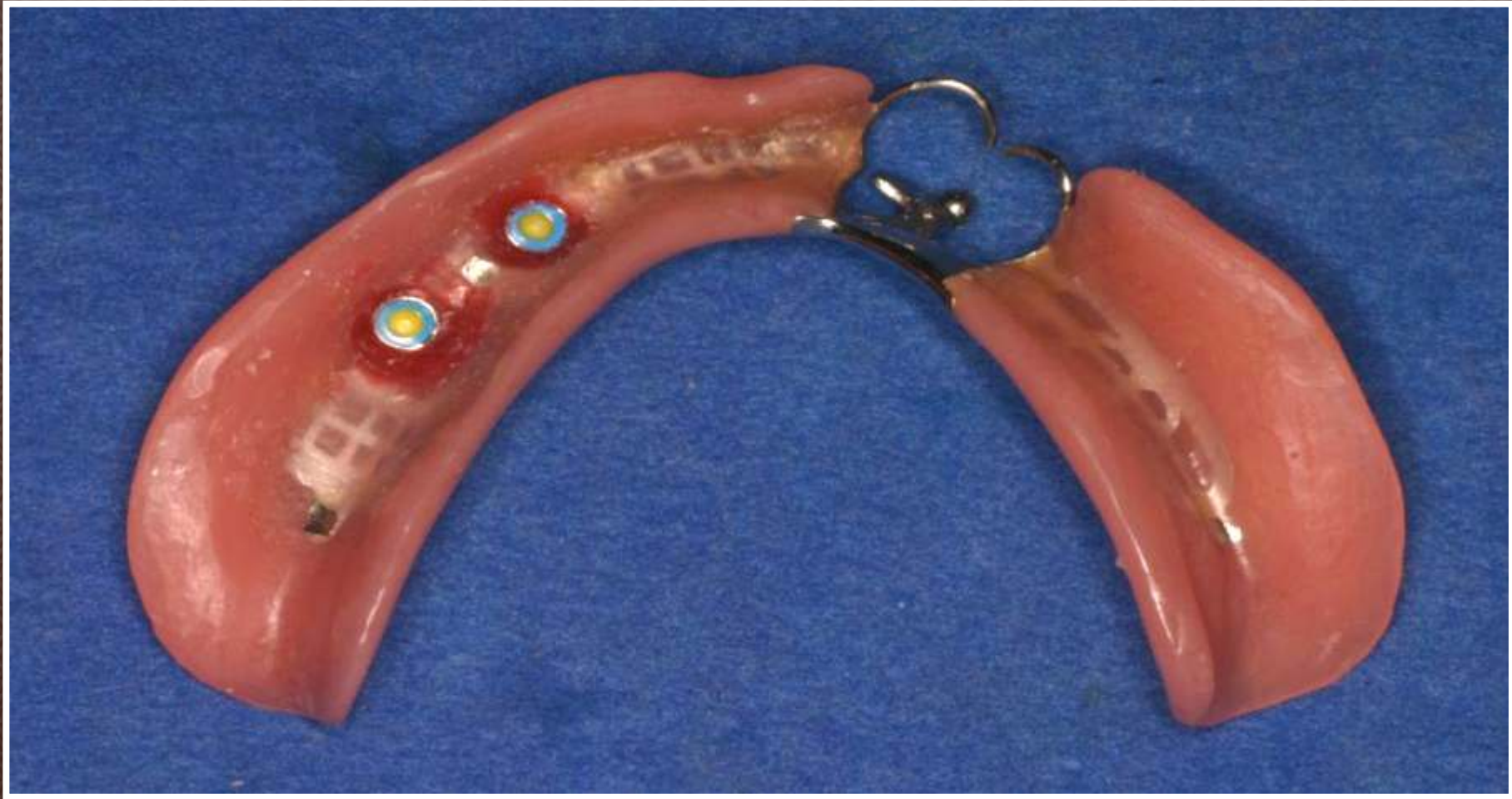By Lee JH

Case



By Lee JH

Case



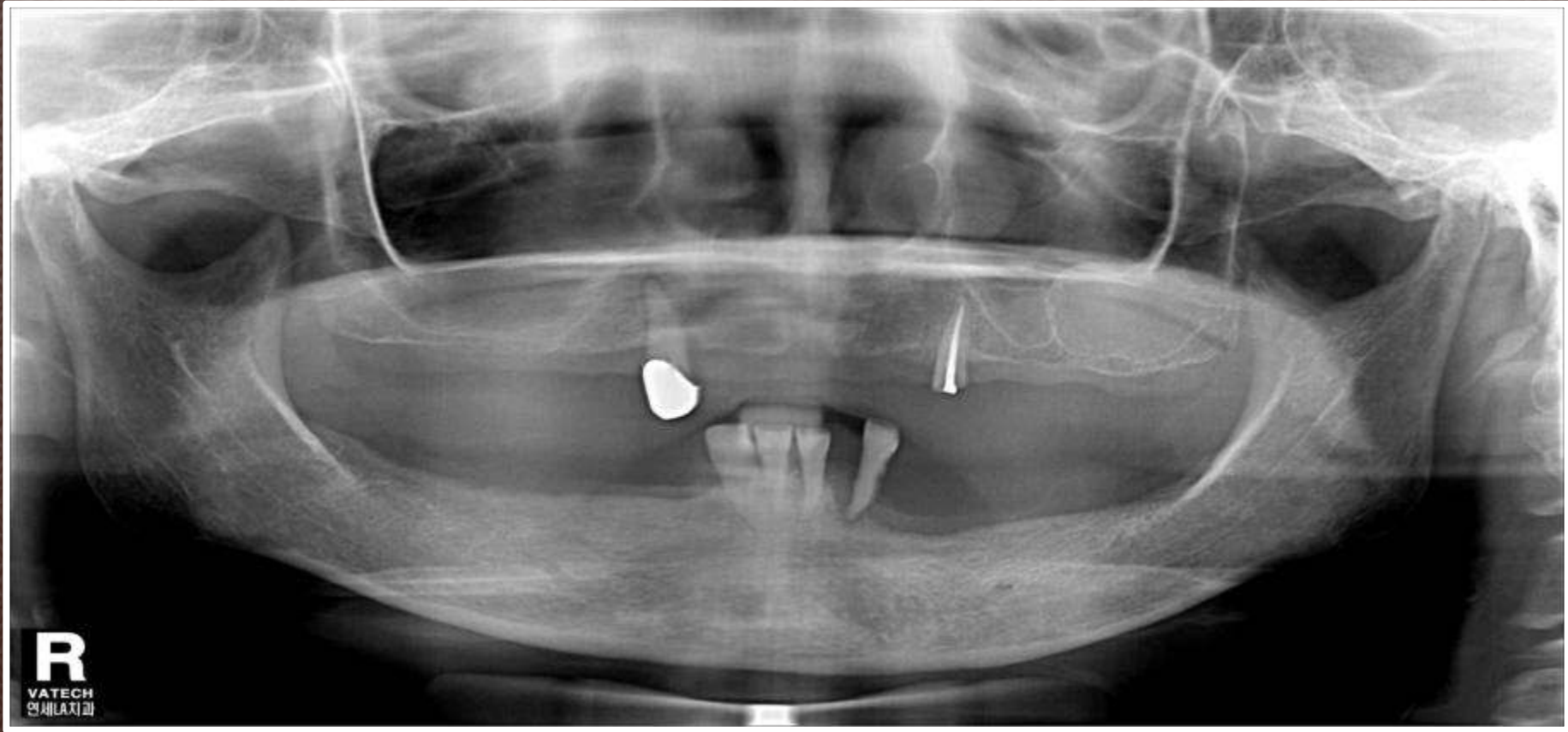
By Lee JH

Advantages

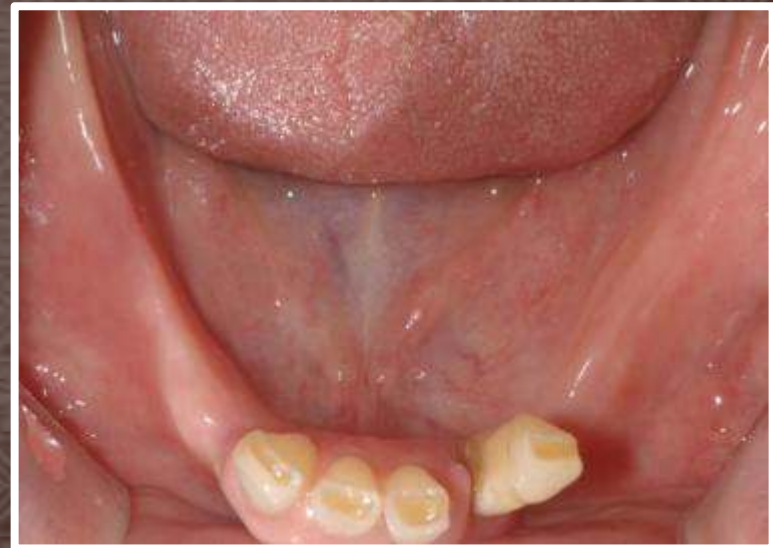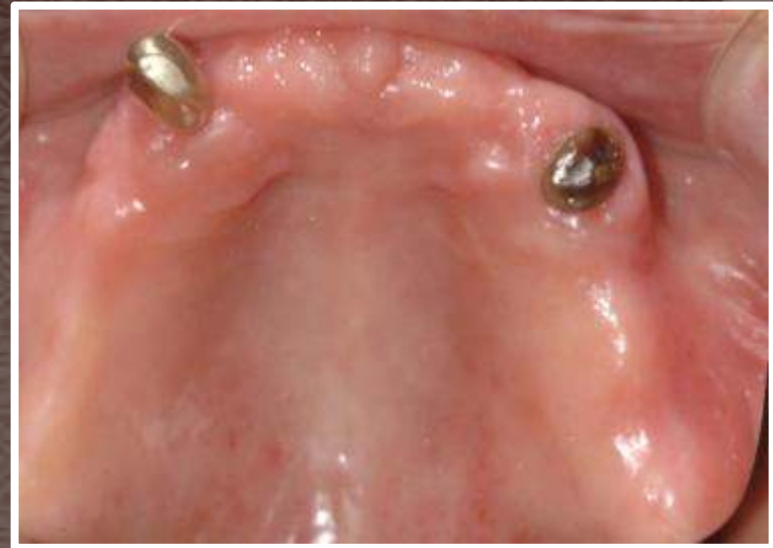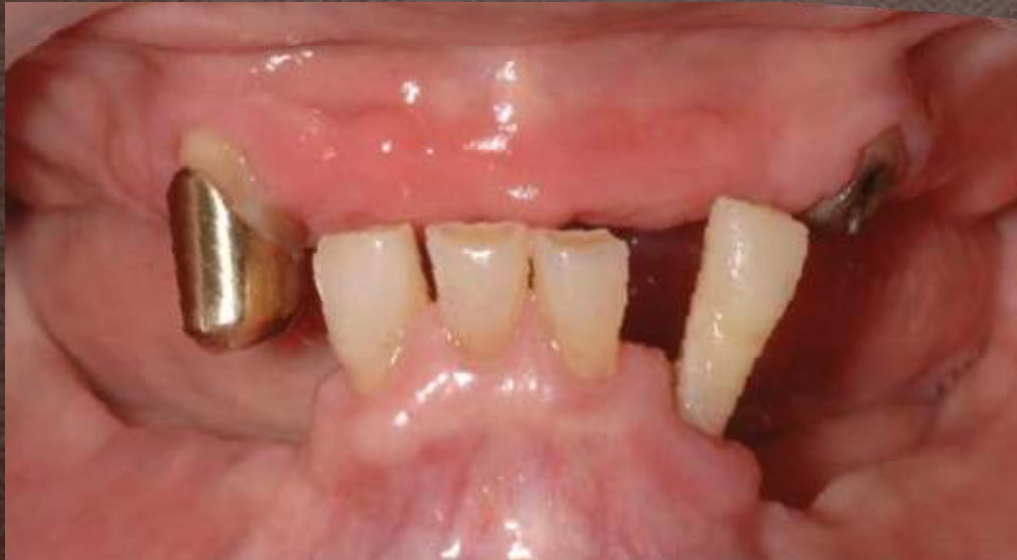- ✿ Use of stud attachment to reduce unfavorable movement and rotation of RPD
- ✿ Enhance retention and stability
- ✿ Bilateral balancing occlusion

Overdenture <Case I>

✿ 57yr old female

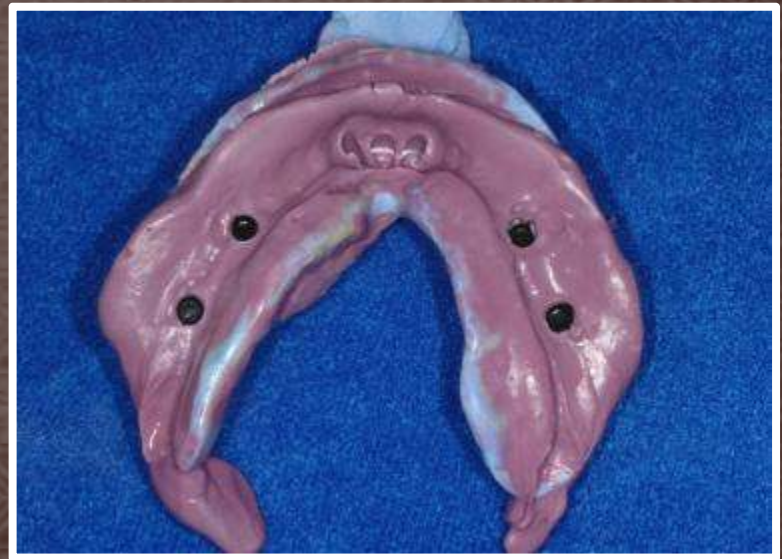
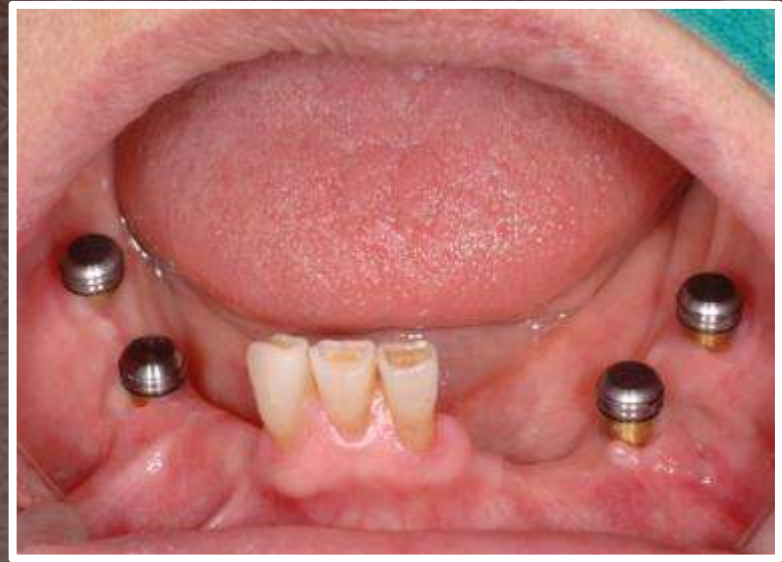
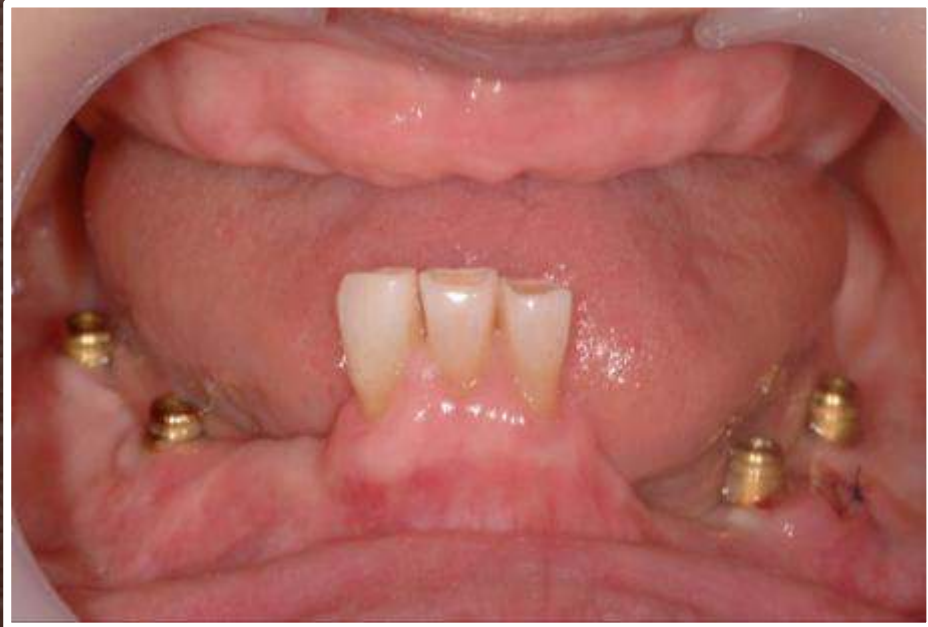
05. 11. 11

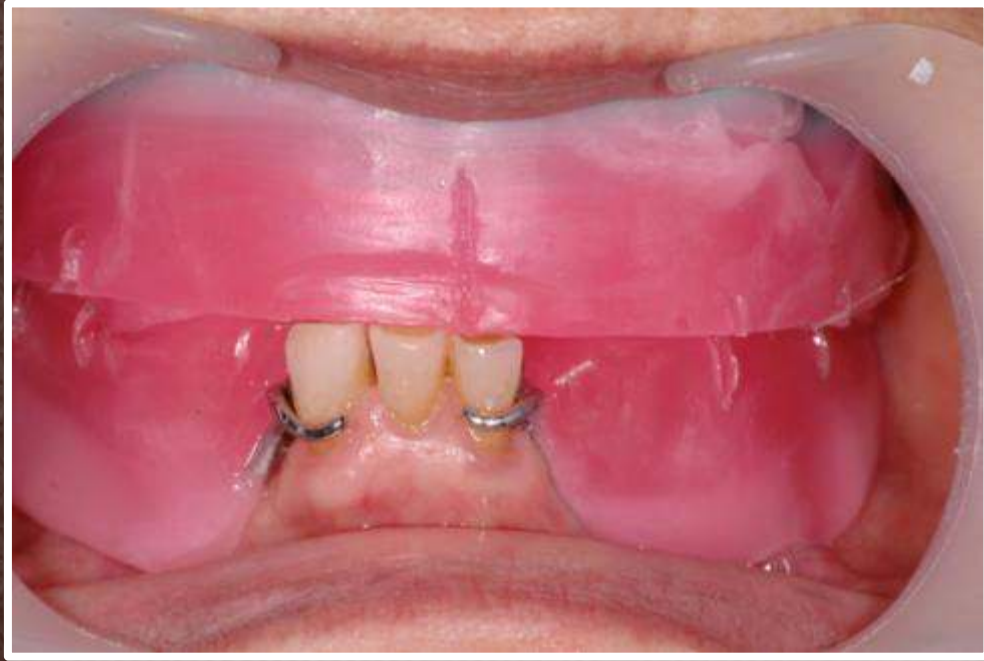

2 lower implants with
attachments
after bone reduction ?

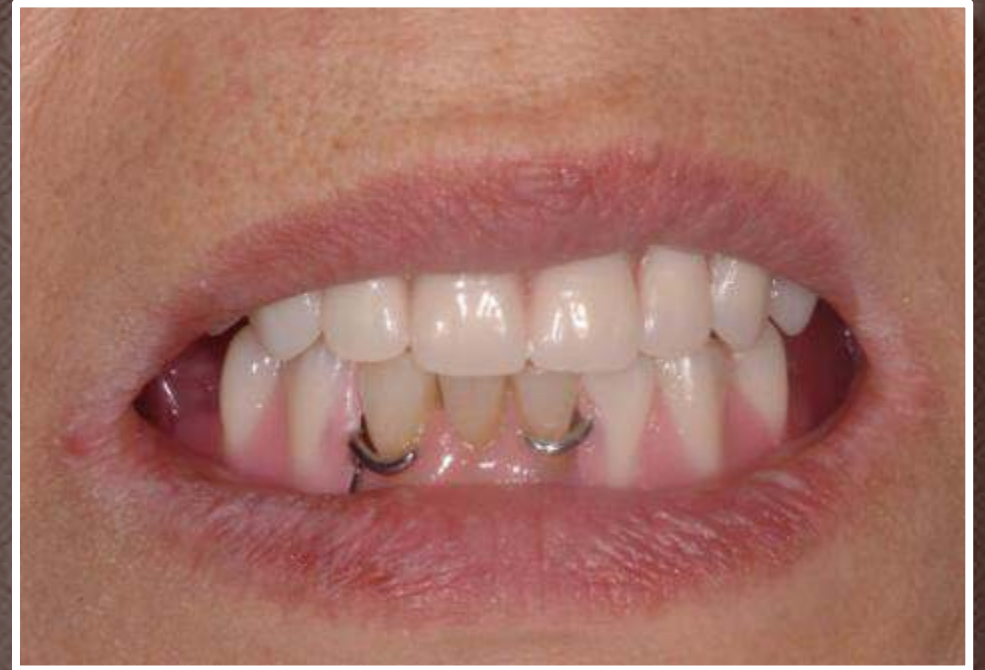05.11.11



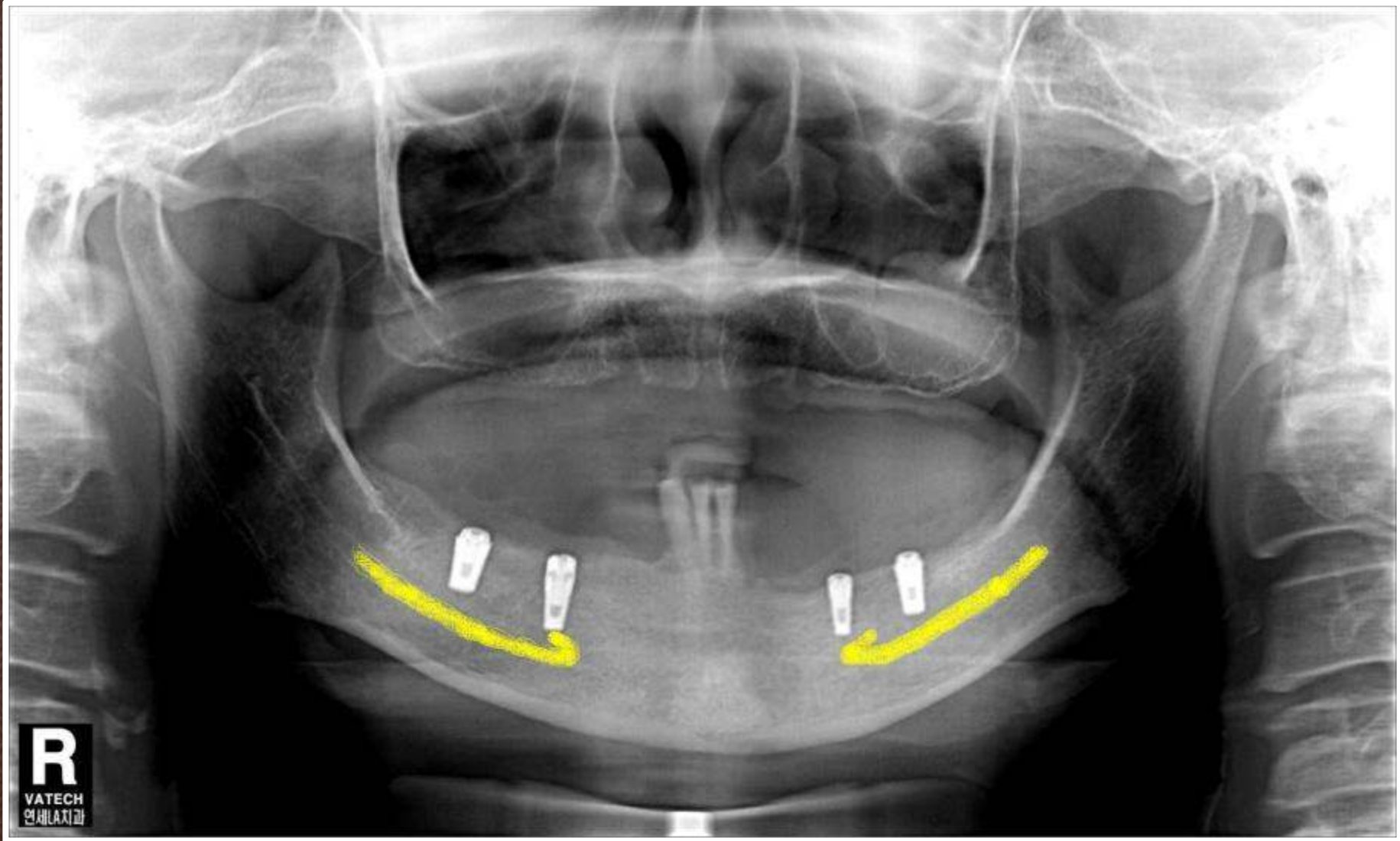
06. 02. 09



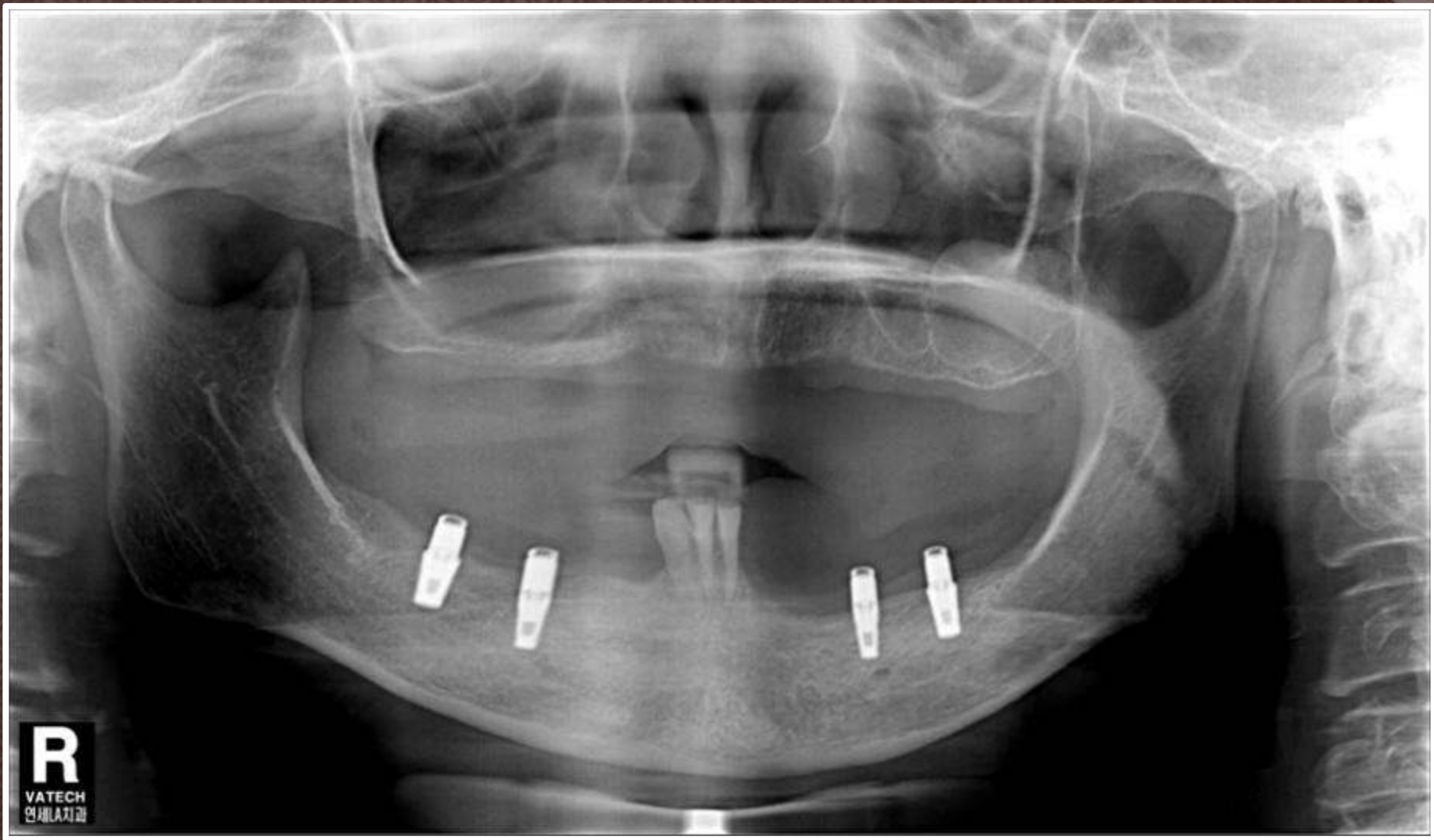
Wax rim



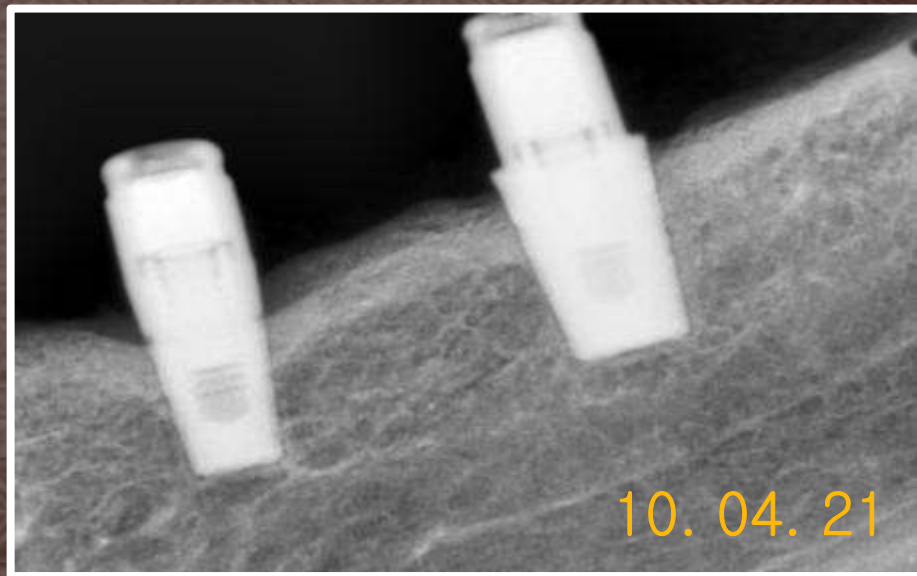

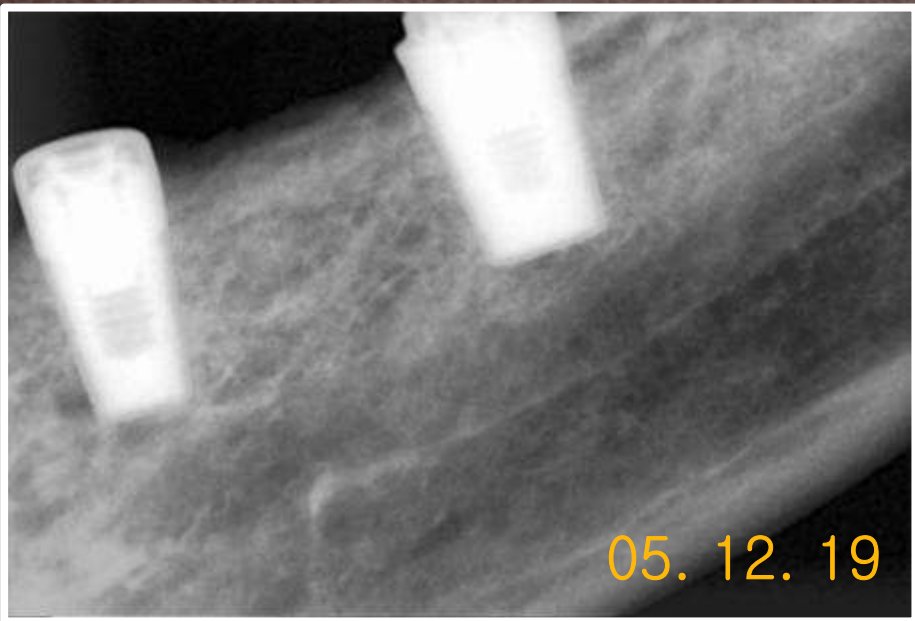
Esthetic try in

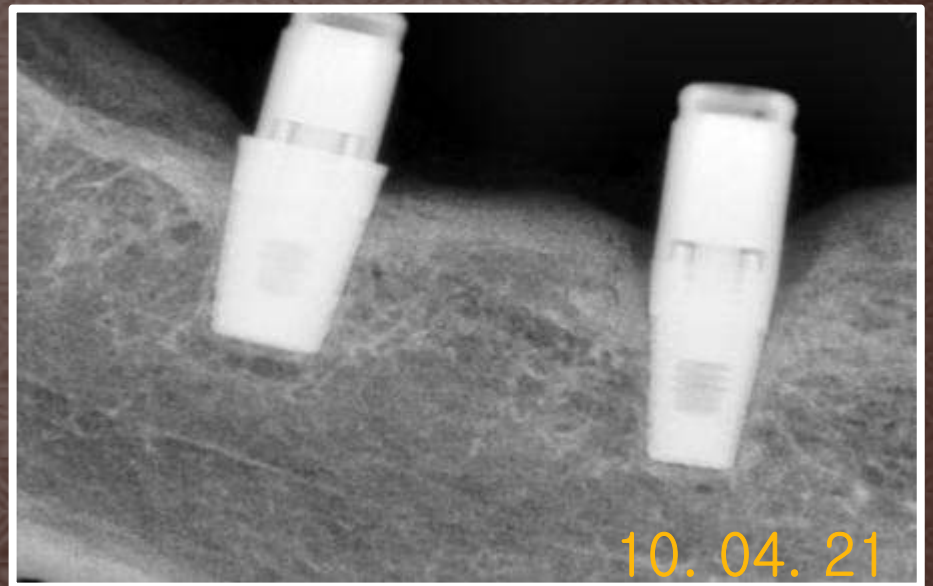
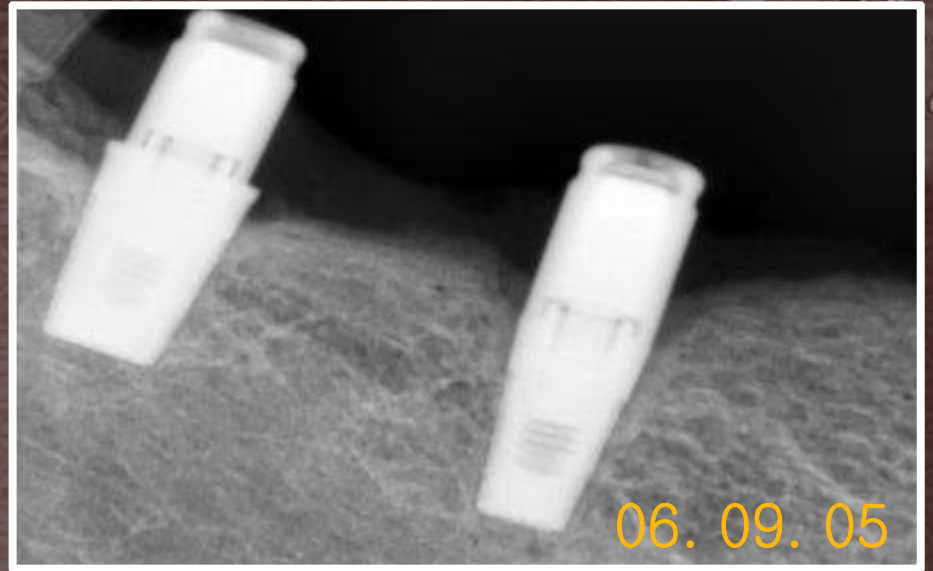
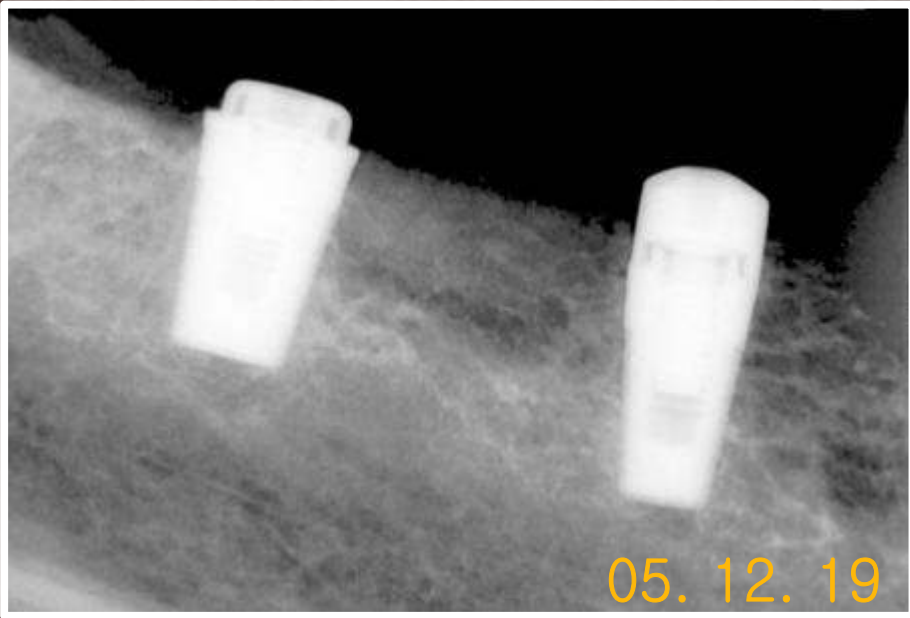


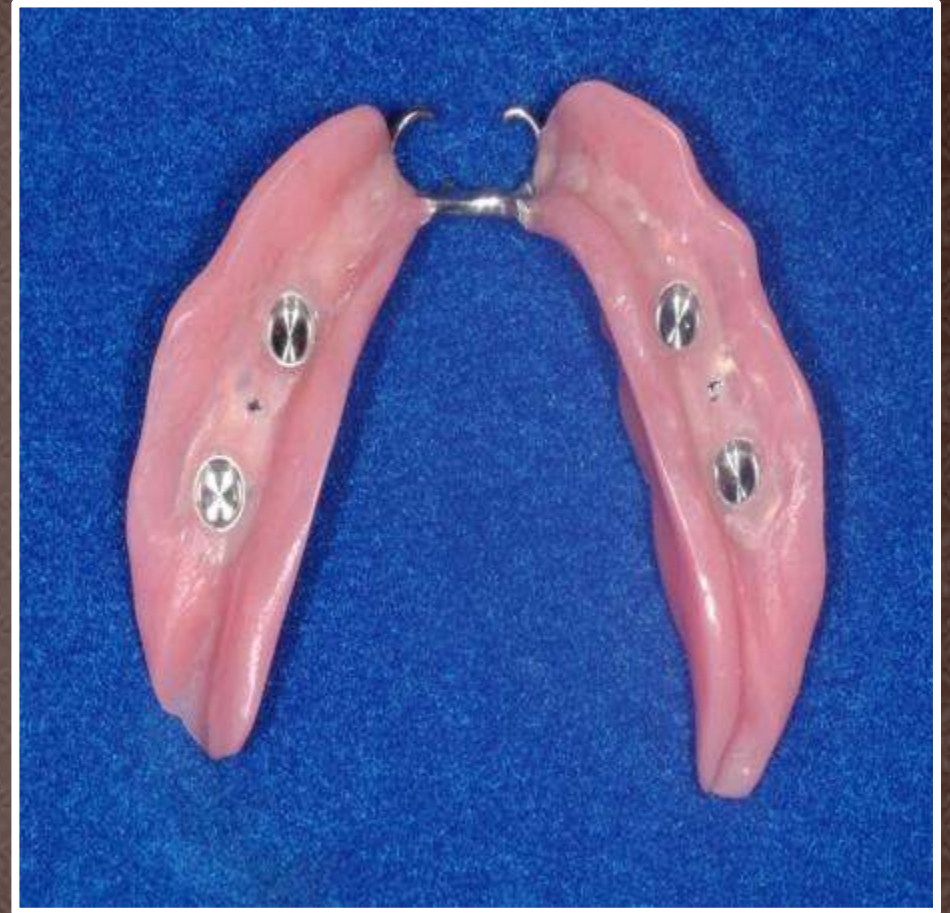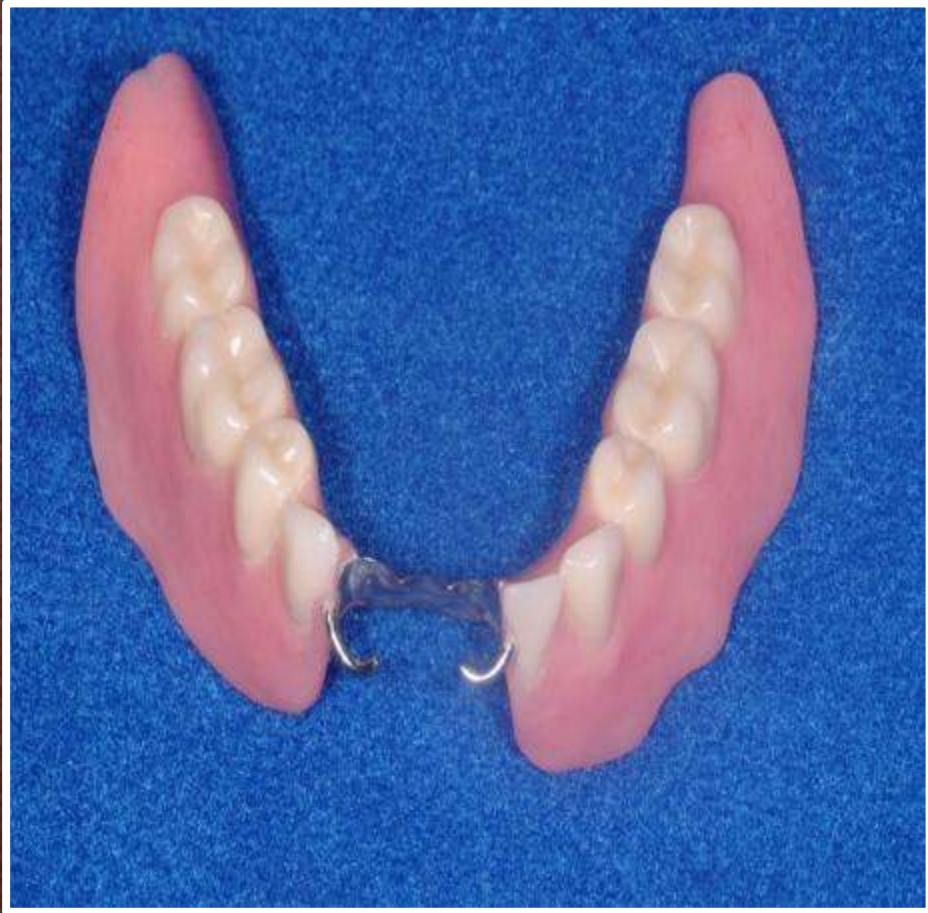05. 12. 01

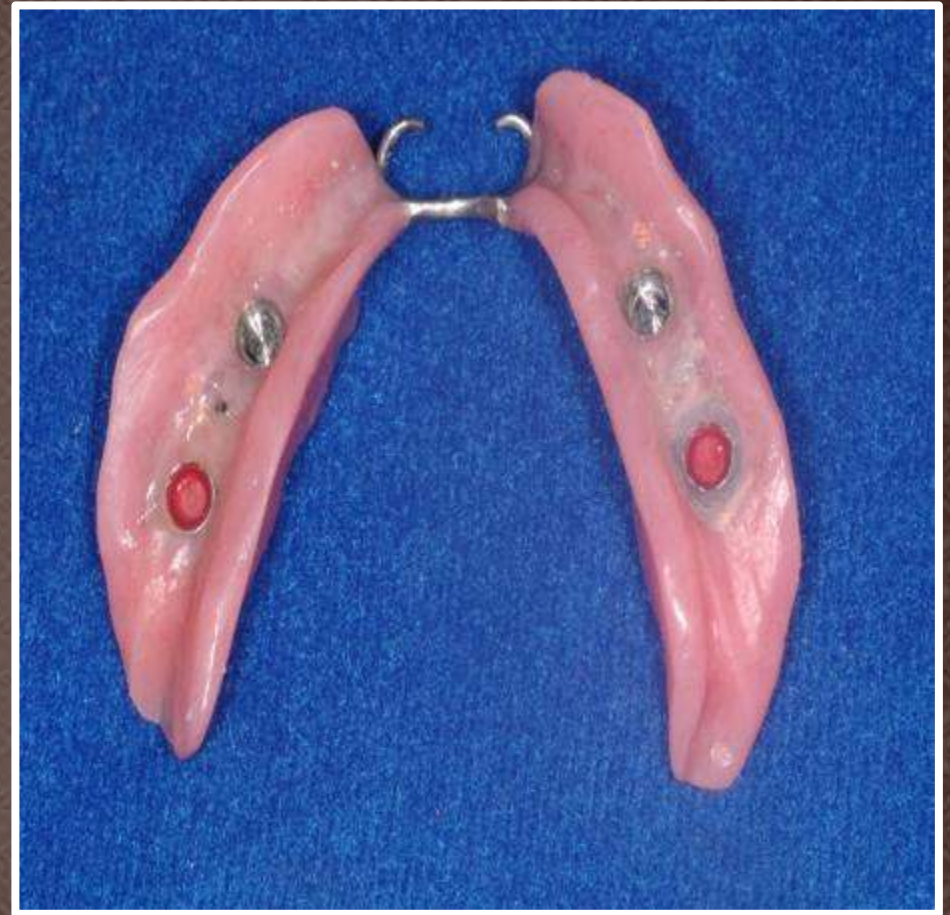
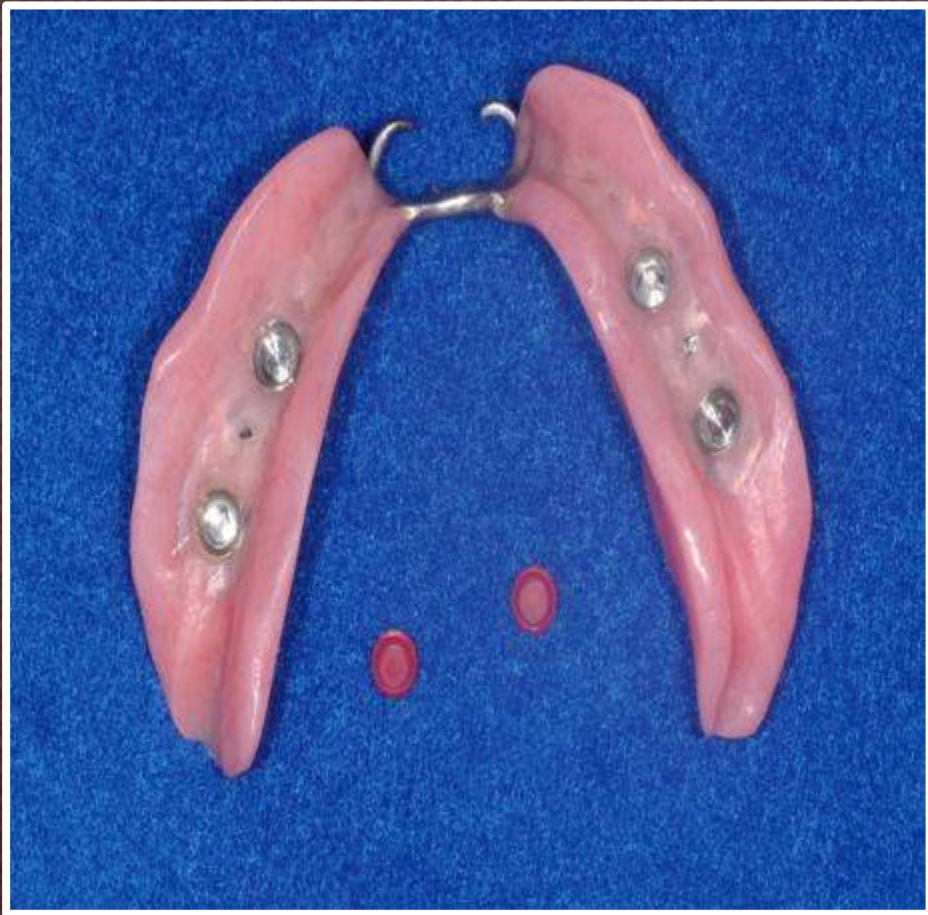
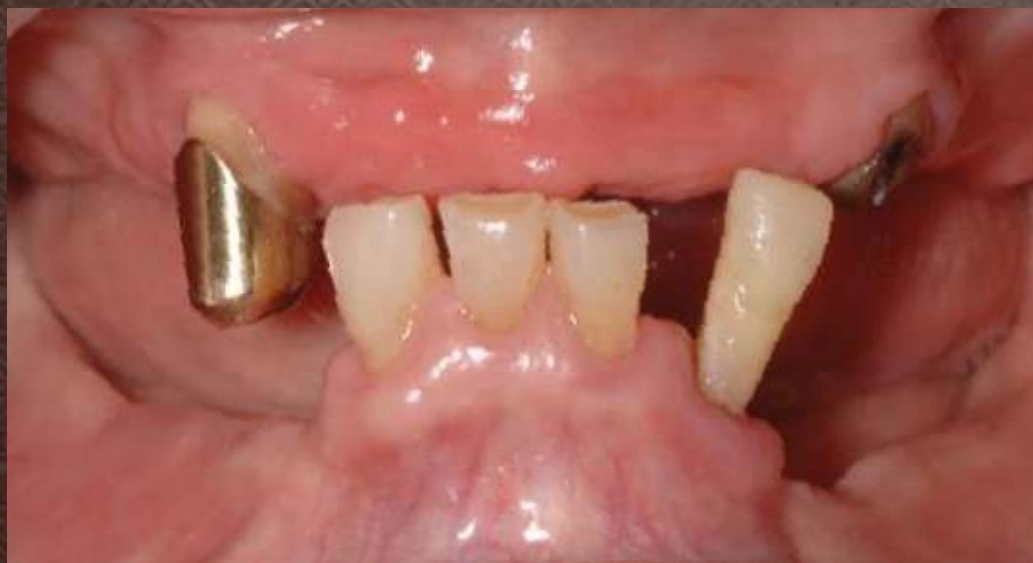06. 02. 27



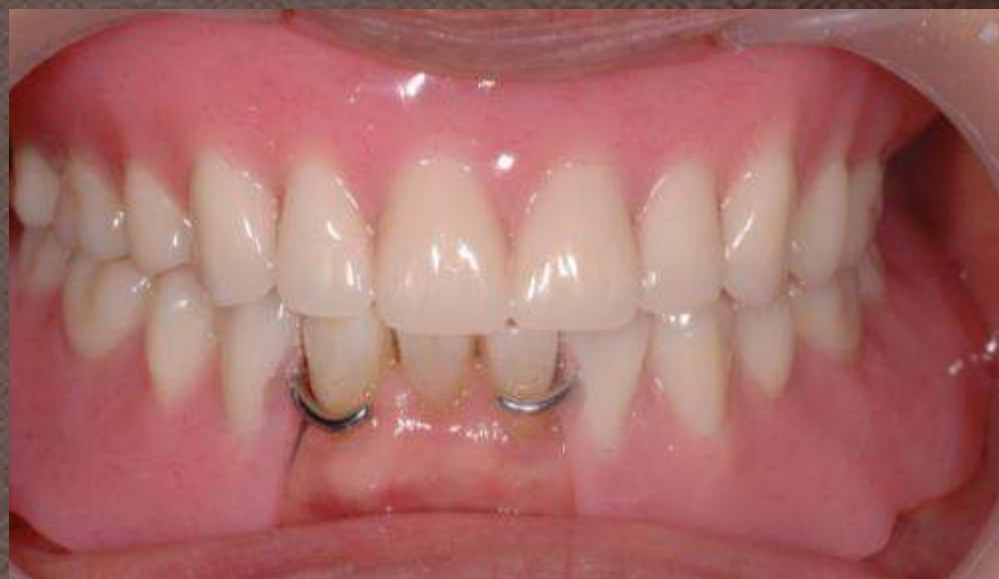




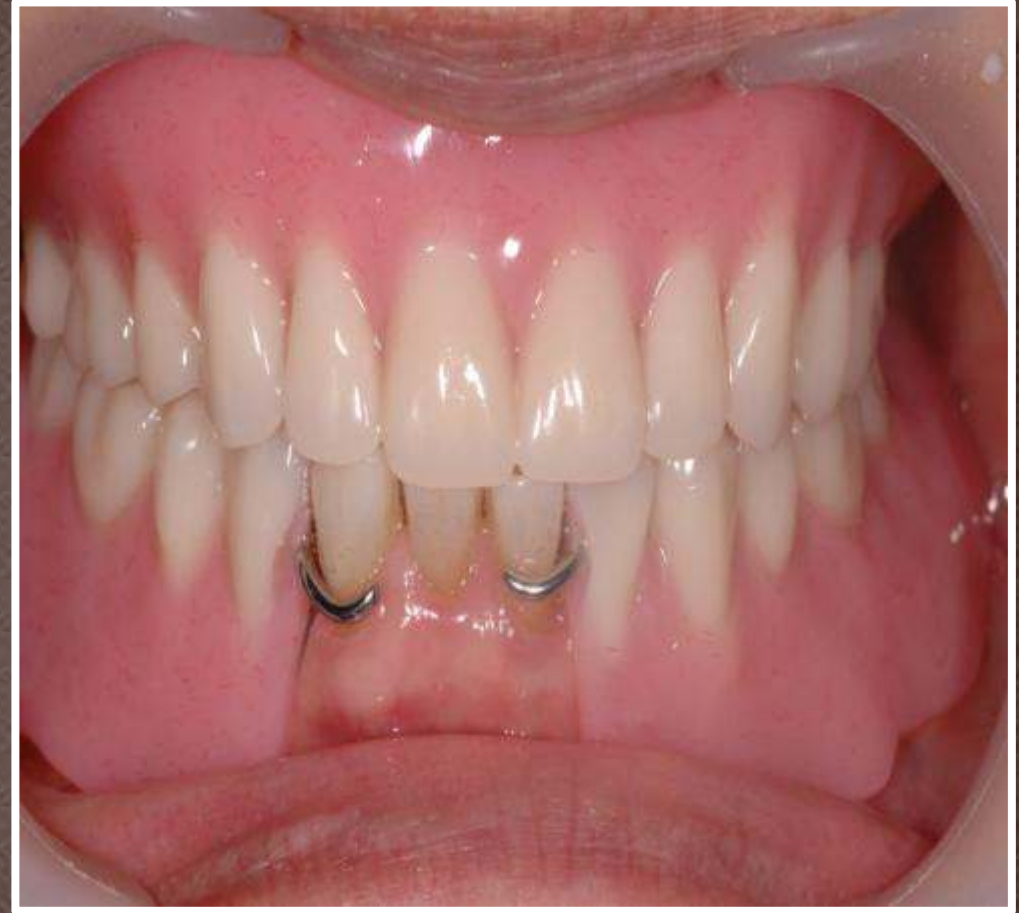
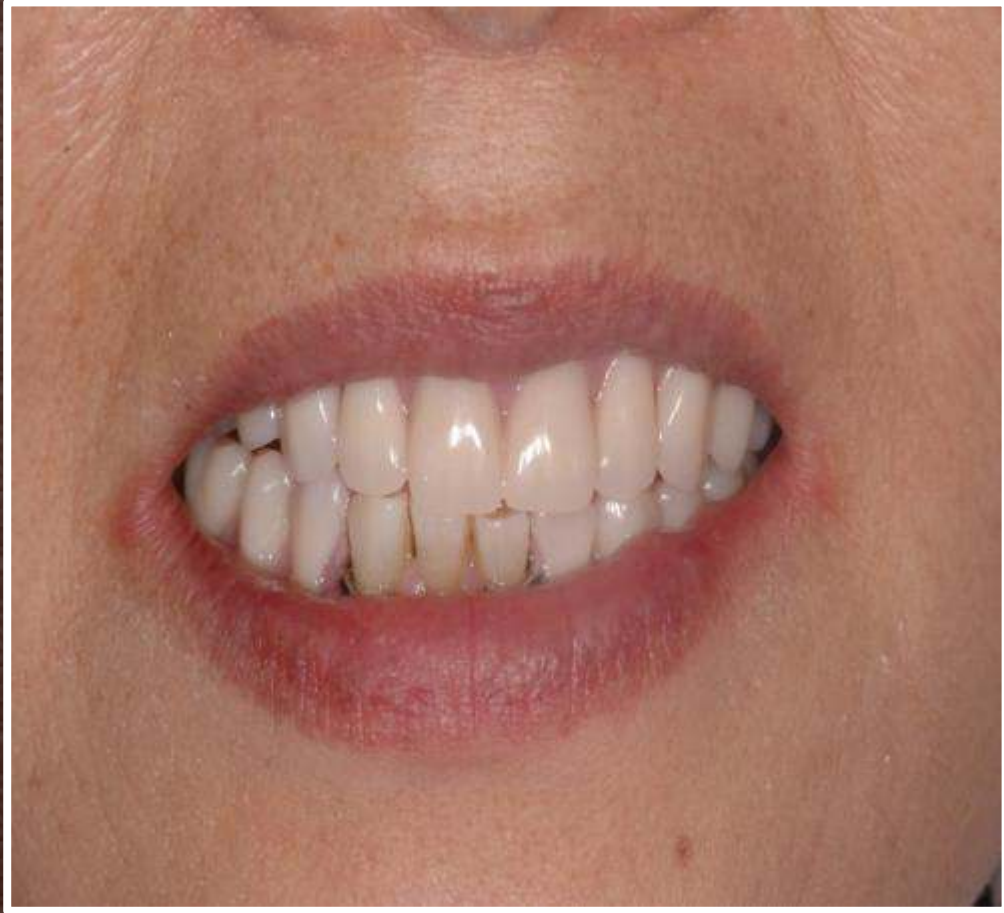

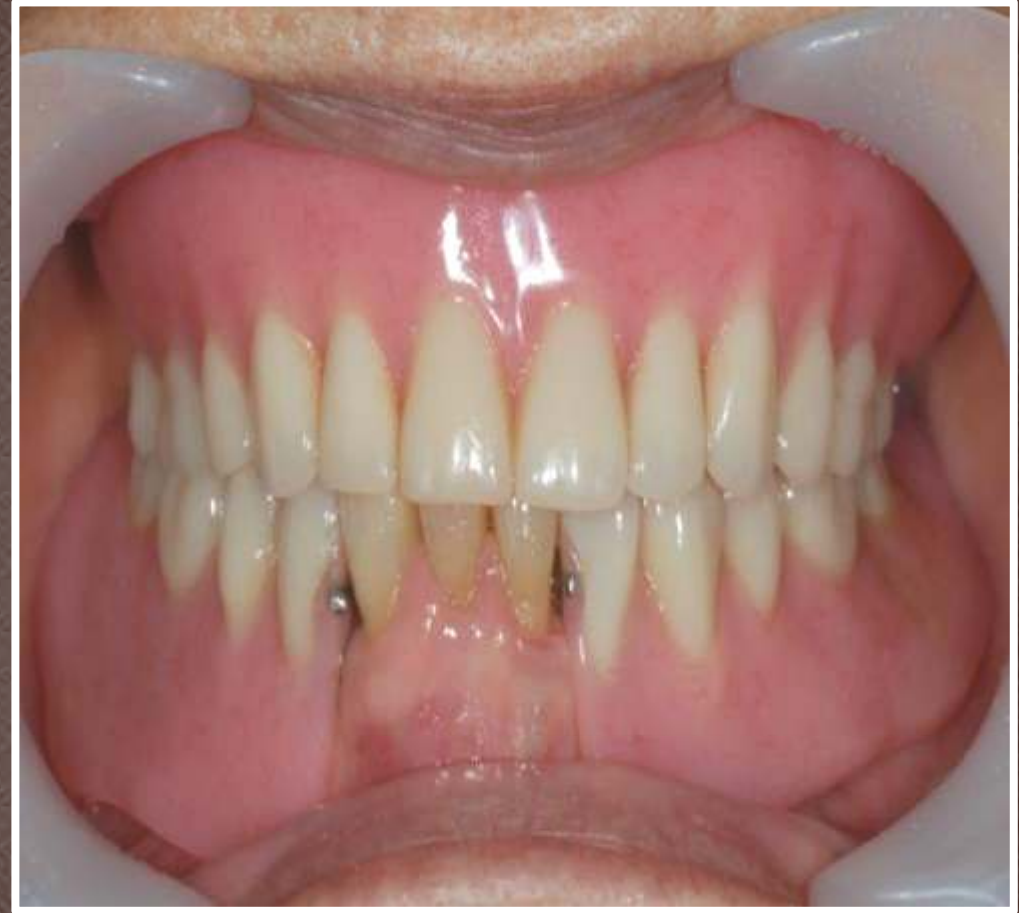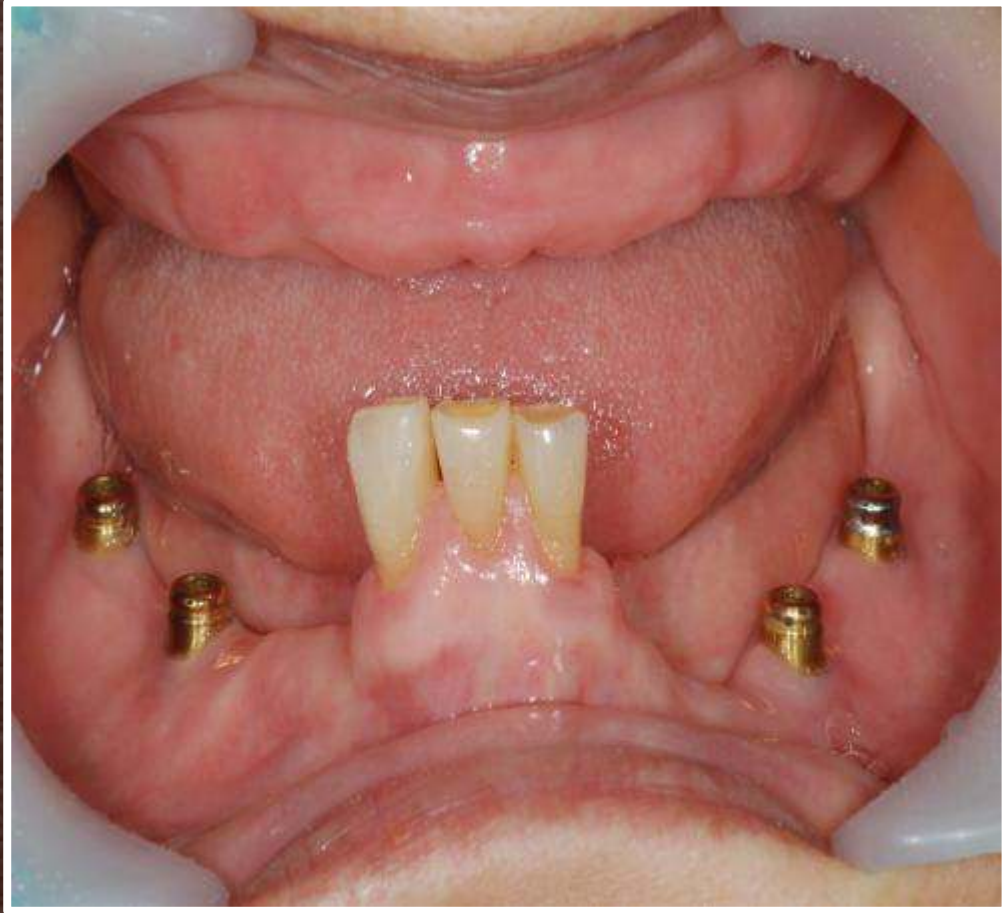05. 11. 11



06. 02. 27



06. 02. 27



10. 04. 21

